

# Cerebellar Motor Function in Spina Bifida Meningomyelocele

Maureen Dennis · Michael S. Salman ·  
Jenifer Juranek · Jack M. Fletcher

Published online: 22 July 2010  
© Springer Science+Business Media, LLC 2010

**Abstract** Spina bifida meningomyelocele (SBM), a congenital neurodevelopmental disorder, involves dysmorphology of the cerebellum, and its most obvious manifestations are motor deficits. This paper reviews cerebellar neuropathology and motor function across several motor systems well studied in SBM in relation to current models of cerebellar motor and timing function. Children and adults with SBM have widespread motor deficits in trunk, upper limbs, eyes, and speech articulators that are broadly congruent with those observed in adults with cerebellar

lesions. The structure and function of the cerebellum are correlated with a range of motor functions. While motor learning is generally preserved in SBM, those motor functions requiring predictive signals and precise calibration of the temporal features of movement are impaired, resulting in deficits in smooth movement coordination as well as in the classical cerebellar triad of dysmetria, ataxia, and dysarthria. That motor function in individuals with SBM is disordered in a manner phenotypically similar to that in adult cerebellar lesions, and appears to involve similar deficits in predictive cerebellar motor control, suggests that age-based cerebellar motor plasticity is limited in individuals with this neurodevelopmental disorder.

---

M. Dennis (✉)  
Program in Neurosciences and Mental Health,  
Department of Psychology, The Hospital for Sick Children,  
555 University Avenue,  
Toronto, ON M5G 1X8, Canada  
e-mail: maureen.dennis@sickkids.ca

M. Dennis  
Department of Surgery, University of Toronto,  
Toronto, ON, Canada

M. Dennis  
Department of Psychology, University of Toronto,  
Toronto, ON, Canada

M. S. Salman  
Section of Pediatric Neurology, Children's Hospital,  
University of Manitoba,  
Winnipeg, MB, Canada

J. Juranek  
Developmental Pediatrics, University of Texas Health Science  
Center at Houston,  
Houston, TX, USA

J. M. Fletcher  
Department of Psychology, University of Houston,  
Houston, TX, USA

**Keywords** Cerebellum · Motor function · Motor learning · Spina bifida · Chiari II

## Introduction

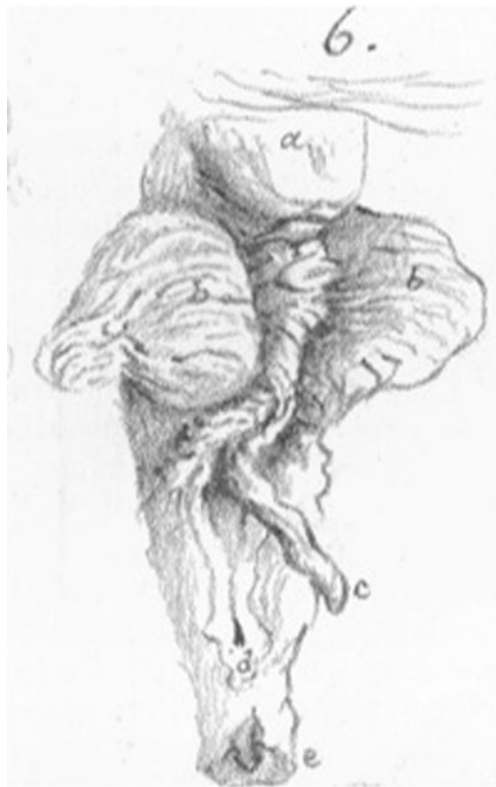Congenital malformations and dysmorphologies of the cerebellum provide a rich and largely untapped source of information, not only about cerebellar motor function, but also about the structural and functional plasticity of the cerebellum under conditions of formative rather than acquired neuropathology. A disorder-specific pattern of cerebellar pathology plays a causative and central role in spina bifida myelomeningocele (SBM), the most common and severe form of spina bifida. SBM is a congenital disorder that occurs because of failure of neural tube closure around 3–4 weeks' gestation. It has a declining (but still significant) prevalence most recently estimated at 2.02/10,000 US births [1]. This paper reviews cerebellar neuropathology and motor function in SBM in relation to current models of cerebellar motor and timing function.

## The Spinal Cord and Cerebellum in SBM

Using post-mortem material, Tulp in 1716 described the spinal lesion of meningocele [2], and Morgagni in 1761 noted the association between spina bifida and lower limb deformities [3]. In SBM, neuron numbers are reduced even in superficially normal segments of the lumbosacral cord [4], with reductions being related to the degree of cord damage or deformity [3]. Spinal cord abnormalities on MRI are evident even in individuals with SBM with no clinical deterioration in spinal cord function [5].

In 1883, Cleland [6] linked the spinal cord lesion to cerebellar dysmorphologies (Fig. 1) and differentiated the more severe thoracic spinal lesions from the less severe lumbar spinal lesions. In 1891, Hans Chiari described three grades of cerebellar abnormalities in patients with chronic hydrocephalus [7, 8], including what is now termed the Chiari type II malformation (Chiari II).

The Chiari II, which occurs almost universally in neonates born with SBM [9], is a congenital anomaly. Specific to the Chiari II malformation are a constellation of prominent structural anomalies involving the cervical spinal cord, brainstem, and cerebellum [10, 11]. Other brain and spinal cord anomalies associated with Chiari II include



**Fig. 1.** Cerebellar dysmorphologies described by John Cleland [1835–1925] in 1883. *a*, Corpora quadrigemina; *b*, hemispheres of cerebellum; *c*, the extremity of the elongated nodule [most inferior portion of cerebellar vermis]

elongated cranial nerves, corpus callosum absence or hypogenesis, syringomyelia, cortical neuronal migration defects, hypoplasia or aplasia of the cranial nerve nuclei, and thalamic deformation [10–13].

The features of Chiari II have been best explained by the popular unified theory [14, 15], which proposes that normal distension of the embryonic ventricular system through the pressure generated from cerebrospinal fluid (CSF) buildup fails to occur in SBM because of CSF leakage through the spinal defect. Lack of ventricular distension in utero limits normal growth of the bony elements of the posterior fossa and results in a small posterior fossa [14, 15]. Consistent with the unified theory are the reduction or prenatal resolution of hindbrain herniation [16–18] and a decrease in the incidence of brainstem compression later on in infancy and early childhood [19] following primary repair of the spinal defect in utero.

The posterior fossa and its contents are attenuated in Chiari II. Individuals with SBM have smaller midsagittal posterior fossa areas and cerebellar volumes, consistent with other post-mortem and radiological investigations showing smaller posterior fossa size and loss of cerebellar gray and white matter [11, 17–19]. In SBM, the midsagittal vermis may expand rostrally, caudally, ventrally, and dorsally, presumably because of compression and its midline location [20, 21]. The cerebellar hemispheres are underdeveloped [17, 22, 23], presumably because they have no room to expand within a narrowed skull [20, 21].

Cerebellar dysmorphology and compression does not affect all cerebellar regions equally [20, 21]. Juranek et al. [24] found total cerebellar volume to be significantly reduced in SBM relative to controls; after correcting for total cerebellum volume, and relative to the typically developing group, the reduction represented a reconfiguration involving anterior lobe enlargement and posterior lobe reduction. Within the corpus medullare, white matter integrity is compromised (fractional anisotropy is reduced) in SBM in the middle cerebellar peduncle, one of the major cerebellar white matter tracts [25].

Histological changes in the herniated cerebellum in SBM include Purkinje and granular cell depletion [26, 27]. Cell populations and DNA content are reduced in the internal granular layer in SBM [21], which also exhibits immature cell collections [12]. Eighty-three percent of SBM cases have half the normal number of Purkinje cells [28]. In addition, 48% of post-mortem brains of individuals with SBM show absence of one or more of the cranial nervous nuclei, basal pontine nuclei, and olivary nuclei, possibly because the pontine and olivary nuclei and the cerebellum all originate from the alar plate of the rhombencephalon [12]. While there is evidence of hypoplasia of the deep cerebellar nuclei in other congenital posterior fossa malformations like Joubert Syndrome [29], no information is

available on the deep cerebellar nuclei in SBM. However, the firing patterns in the deep cerebellar nuclei are controlled primarily by the number of concurrently active Purkinje cells, their firing rate, and level of synchrony in the transition from continuous firing to quiescence [30], so deep cerebellar nuclei in SBM may be suboptimally functional because of the loss of Purkinje cells.

Cerebellar dysmorphisms are primary features of the neuropathology of SBM and generate a cascade of events that involves changes in the development of subtentorial and supratentorial brain regions. Some of these changes are a direct mechanical effect of the state of the posterior fossa and cerebellum, involving obstruction of CSF flow that may require shunt diversion treatment. Others are related to cerebrospinal fluid abnormalities originating in the embryonic vesicles that produce secondary dysplasias and hypoplasias.

Development of the contents of the posterior fossa, the cerebellum and related structures, is constrained by the small posterior fossa [31]. Crowding of hindbrain structures within a small posterior fossa is responsible for the features of Chiari II [15], which include downward herniation of the cerebellum and hindbrain into the foramen magnum, towering of the vermis above the tentorium cerebelli, distortion of the midbrain tectum in the form of a beak (“tectal beaking”), and mechanical abnormalities of the medulla [32]. The corpus callosum shows complex patterns of agenesis and hypoplasia along a rostral–caudal axis, with rostrum and splenium regions likely to be agenetic [33]. In SBM, the posterior cortex is thinner than the anterior cortex [34], which is larger than that of controls [35], and studies of cortical regions have revealed complex patterns of thickening, thinning, and gyrification [33]. This pattern leads to strengths and weaknesses in multiple cognitive domains [36], some of which reflect the impact of hydrocephalus and its treatment [37]. Here, we focus on motor function in SBM and its relation to the effects of isolable and specific cerebellar abnormalities.

### Motor Function in SBM

As more individuals with spina bifida survived, motor deficits were reported in the lower limbs [38], trunk and upper limbs [39], speech articulators [40], and ocular motor system [41]. While clinical motor studies have described disturbances of motor function, newer experimental investigations have attempted to characterize the deficient motor processes.

Differences in cerebellar motor function between children with SBM (for the most part, of average verbal intelligence) and typically developing age peers include functions representing the classical cerebellar triad of ataxia (limb instability), dysmetria (errors in the metric of

movement), and dysarthria (impaired motor speech). Differences also occur on tasks involving motor timing and rhythm, which are essential components of movement [42]. In fact, timing and rhythm impairments are part of the historical role of the cerebellum in movement. For Gall et al. [43], the cerebellum was “the balancer and regulator of locomotive movements” [p. 113], “an organ for the regularity of locomotive movements separate from the organ of these movements themselves” [p. 119]. In 1902, Babinski [44] described a cerebellar asynergia, which involved arrhythmic decomposition of movements. Holmes [45] thought the cerebellum regulated the timing and rhythmicity of movement, not movement itself; he described motor deficits following cerebellar damage as involving: “a lack of synchronicity in the separate components of the movement” [p. 17]; “a delay in the initiation of one component relative to another” [p. 18]; and “in actions requiring reversal of direction there is the slower rate and the lack of rhythm” [p.19].

In SBM, cerebellar motor skills vary across tasks (some motor functions are intact while others are impaired) and between individuals within tasks. Although not obviously age dependent, variability in the presence of certain motor functions may be related to the level of the spinal lesion and the nature/extent of the cerebellar malformation. Wherever possible, we will describe these sources of variability.

### Lower Limbs

Delay in ambulation occurs in nearly all children with SBM, including those with lower level spinal lesions, although children with upper level spinal lesions are more compromised [46]. The spinal cord lesion causes a profound disruption of gait; however, because mobility status is related to upper limb function [47], Chiari II abnormalities may contribute to lower limb deficits.

### Trunk and Upper Limbs

*Function* Upright stance is intrinsically unstable. Deviations from the upright body position produce a destabilizing gravity-induced torque, which is countered by a corrective torque from small corrective body deviations, termed postural sway. Relative to typically developing age peers, children with SBM have impaired posture [48, 49] and adults with SBM also have poor postural stability [50], suggesting truncal ataxia. Höglund and Norrlin [51] measured the amplitude, velocity, and frequency of center of pressure displacement of postural sway, and found that individuals with SBM had difficulty maintaining posture by making small corrective body deviations.

In two recent studies of upper limb function in children [52] and adults [50] with SBM, quantitative coding

schemes were used to evaluate principled components of upper limb function under standard conditions and conditions of physical or cognitive challenge, such as would be encountered in performing the tasks in daily life: eyes open (no counting), eyes closed (no counting), eyes open and counting backward from 50, and eyes closed and counting backward from 50. On a *limb dysmetria* (finger–nose–finger) task, children in the SBM group were slower but as accurate than age peers for all challenge conditions; within the SBM group, children with lower level spinal lesions performed faster than those with upper level spinal lesions [52]. Adults with SBM performed less well than age peers on the limb dysmetria task, and were more disrupted than controls by the challenge of counting [50]. On a *diadochokinesis* (rapidly alternating hand movement) task, children with SBM were both slower and less accurate than controls on all challenge conditions [52]. Adults with SBM were slower than age peers on the diadochokinesis task [50].

Granted their limb dysmetria and ataxia, it is not surprising that children with SBM often have difficulties with upper limb and hand function on everyday tasks such as eating, turning, stacking, lifting, and opening [53–55]. In addition, they have difficulties in fine motor control of arms and hands [56–61], coordination [57, 62–65], drawing [66–68], and handwriting [69, 70].

*Cerebellum* Adults with cerebellar lesions exhibit a limb ataxia that is correlated with the presence of intermediate and lateral sagittal cerebellar lesions [71]. The deficit in upper limb movement in SBM may be related to a reduction in size of the cerebellar hemispheres, where limb movements are generally processed, although this has yet to be tested with quantitative methods for cerebellar parcellation.

### Motor Speech

*Function* Ataxic dysarthria involves three motor speech clusters [72, 73]. *Articulatory inaccuracy* includes imprecise consonants, irregular articulatory breakdowns, and distorted vowels; it has been associated with inaccuracy of repetitive movements [72, 73]. *Prosodic excess* includes excess and equal stress, prolonged phonemes, slow speech rate, and prolonged intervals between words and syllables; it has been related to motor slowing [72, 73]. *Phonatory–prosodic insufficiency* includes harshness, monopitch, and monoloudness, and may be associated with hypotonia of speech musculature [72, 73].

Individuals with SBM have dysfluent speech [56, 74]. Huber-Okraïnc et al. [75] reported that compared with controls, both children and adults with SBM had more deficits in motor speech, including dysfluency, ataxia

dysarthria, and speech rate, with ataxia dysarthria being greater with upper rather than lower spinal lesions.

*Cerebellum* Cerebellar lesions disrupt the coordination of prosody, articulation, phonation, temporal regulation, and fluency of speech production [76]. Ataxic dysarthria in SBM is consistent with the cerebellar role in speech, according to which the cerebellum calibrates smooth and rhythmically sculpted words and phrases at the individual's habitual speech rate [77].

### Eye Movements

*Function* Ocular and ocular motor disturbances described in many individuals with SBM include impaired smooth ocular pursuit, saccade (i.e., fast, ballistic eye movements between two stationary objects) dysmetria, impaired performance of the vestibular–ocular reflex, various forms of pathological nystagmus (abnormal ocular oscillations), strabismus, and internuclear ophthalmoplegia, a type of gaze palsy causing double vision [78–88].

Saccades rapidly bring images on the fovea, where spatial acuity is best. Saccades are typically accurate and age appropriate in SBM [89]. Another function of vestibular, fixation, and smooth pursuit eye movements is to keep images still on the fovea, which enhances spatial resolution. Many individuals with SBM have a normal angular vestibular–ocular reflex (VOR) performance in response to active head motion [90], and fixation stability is similar to that in healthy controls [91]. However, smooth ocular pursuit is generally impaired in individuals with SBM and nystagmus, although not in those without nystagmus [92].

*Cerebellum* The cerebellum participates in visual fixation, binocular alignment, saccade accuracy, smooth ocular pursuit generation and maintenance, VOR modulation, and adaptations of saccades, smooth pursuit, and the VOR to altered visual information and to disease [83]. The basic VOR is a brainstem function, although the cerebellum is involved in VOR modulation (e.g., how the eyes move in response to head movements when we wear a magnifying lens), which has not been studied in SBM. Vermis lobules VI and VII (the ocular motor vermis) and the fastigial nucleus determine saccade accuracy [93], the flocculus and paraflocculus regulate image stabilization on the retina [94], while the nodulus and ventral uvula (vermis lobules IX and X) are important for vestibular velocity storage mechanisms [83] and transforming head-centered vestibular afferent signals into earth-referenced self-motion and spatial orientation signals [95].

In adults, cerebellar vermis lesions produce saccade dysmetria and jerky pursuit, and the dorsal vermis is activated during saccadic adaptation [96]. The typically normal saccade accuracy and saccadic adaptation in SBM



suggests intactness of the ocular motor functions of cerebellar vermis lobules VI and VII and the fastigial nuclei, which maintain the accuracy of the open-loop portion of eye movements and so are required for optimal saccadic function [93, 97].

The difference between preserved saccades and impaired smooth pursuit in SBM may involve the nature of the control system and/or group or individual differences in the underlying cerebellar neuroanatomy. Saccades involve continuous local feedback during the actual saccade until the target falls on the fovea; saccades are over so quickly that there is no time for online visual feedback (which takes at least 100 ms). To be sure, even saccades involve some predictive, feed-forward processes because the brain uses a copy of the oculomotor command that initiated a saccade to predict the new retinal target location (remapping), even though the image of the target remains visible after the saccade [98]. Smooth pursuit is under open-loop visual feedback control, so involves more predictive adjustments. Beyond the pontine level, all smooth pursuit pathways pass through the cerebellum and animal work suggests that two sites within the cerebellum cause smooth pursuit disorders: those of the flocculus/paraflocculus and the vermis, including lobules VI, VII, the uvula, and the deep cerebellar nuclei [99].

In individuals with SBM, ocular motor function is correlated with two alternative patterns of cerebellar development [100]. The first involves reduction in total and lateral cerebellar volumes, expansion of the midsagittal cerebellar vermis area including vermis lobules VI and VII (which are important for saccade accuracy), and relative preservation of the medial cerebellar volume. This pattern of dysmorphology is associated with *sparing* of ocular motor functions of saccadic accuracy and smooth pursuit. The second involves severe cerebellar volume reduction, relative reduction of the medial cerebellum volume, and no expansion of the midsagittal vermis. This pattern is associated with *impairment* of the same ocular motor functions of saccadic accuracy and smooth pursuit. In SBM, the smooth pursuit system is affected most by variations in vermis midsagittal area or cerebellar volume, likely because the flocculi, part of the inferior posterior lobules, are most affected by volume reductions [100].

### Motor Learning

**Function** Experimental tasks using a range of motor paradigms have revealed error-based motor adaptation and learning to be largely intact in children with SBM. In the eyes, individuals with SBM showed intact saccadic adaptation on a saccadic adaptation paradigm in which the target jumps back after a saccade is initiated, simulating overshoot

dysmetria [101]. Children with SBM adapt to prism-distorted visual input [102], learn to trace the outline of a star while looking at its reflection in a mirror [103], and learn a manual rotation task [104]. They also adapt to changes in the relation between arm movements and vision on an elbow goniometer task, on which participants make fast ballistic arm movements to match a target alternating between two positions on a computer screen; after baseline rate and accuracy are measured, the gain is changed to test compensatory adaptation [105]. On tasks of motor learning, motor performance is variable, ranging from intact ballistic arm movements [105] to impaired mirror drawing [103].

Children with SBM show adaptation aftereffects (the persistence of the learned change in movement when the initial, pre-adaptation, conditions are reinstated) on tasks involving prism-distorted visual input [102], mirror drawing [103], and ballistic arm movements [105]. However, the persistence of learned changes in movement over long periods of time has not been evaluated.

**Cerebellum** The cerebellum has been implicated in motor learning [106, 107]. Adults with cerebellar lesions do not adapt to prismatic distortion [108] and show impaired motor adaptation on a ballistic arm movement task [109].

Preservation or enlargement of regional cerebellar size in individuals with SBM may facilitate learning and adaptation. Saccadic adaptation involves vermis lobules VI and VII, which are generally normal in SBM [24].

Brain regions that constitute the cerebello–cortical and striatal–cortical motor loops are important for motor learning [110–112]. In healthy young adults, the cerebellum and basal ganglia show different fMRI peak activation patterns during motor sequence learning [113], and the cerebellum is more widely activated than the basal ganglia in the later stages of motor learning and performance [114]. To date, functional studies of these motor loops during motor learning have not been investigated in SBM.

The basal ganglia appear visibly normal on clinical MRI scans in SBM, and there are some reports of greater fractional anisotropy in one basal ganglia region [115], and mirror drawing learning is faster for those individuals with SBM with more pericallosal gray matter volume, an area including the basal ganglia [103]. Changes in the corpus striatum, including enhanced regional volumes in some parts, may contribute to motor learning in individuals with SBM, but this remains to be tested empirically. In addition, because adaptive learning is related to the anterior cerebellum and adaptation aftereffects to the superior cerebellum including lobules V and VI [116], it will be important to investigate the relation of regional cerebellar development to learning and adaptation aftereffects, and long-term retention.

## Timing and Rhythm

*Function* The term timing refers to different timescales, from milliseconds to estimates of the duration of events of the order of minutes, hours, or days. The subsecond timing system operates in the millisecond range, is used in discrete-event (discontinuous) timing, and involves the cerebellum; the suprasedond system is a continuous-event, cognitively controlled timing system that works in the seconds range and beyond, requires attention, and involves the basal ganglia and related cortical structures [117]. Rhythm concerns subjective accents and their distribution in time and is defined by temporal properties such as tone duration [118] and durations between onsets of consecutive tones [119], the latter determining rhythm perception [118], and involves the cerebellum as well as supratentorial structures.

Children with SBM have difficulties in perceiving subsecond (~400 ms) temporal durations even when they are able to accurately perceive pitch [120]. They are impaired in discriminating rhythms [121, 122]. In producing rhythms, they perform better at synchronization (responding to the beat or tactus of an external rhythm) than entrainment (responding based on an internally generated model of the rhythm so as to produce the rhythm predictively); the deficit rests in the timing rather than in the motor component of the rhythmic tapping [120].

## Cerebellum

A range of evidence implicates the cerebellum in subsecond timing. The response patterns of Purkinje cells are altered during acquisition of new learned timing [123], indicating that these cells are sensitive to the timing of events in the milliseconds range. Learned timing relies upon long-term depression of Purkinje cells [124]. Braitenberg [125] suggested that the parallel fibers in the cerebellar cortex act as a delay system to provide timed signals. More generally, Ivry [126] has proposed that the cerebellum includes a central timer, and Molinari et al. [127] have suggested that timing is within the parameters under cerebellar control that optimize sensorimotor synchronization.

Perception of subsecond time intervals (around 400 ms) is consistently impaired in adults with acquired cerebellar lesions [128, 129], in children with congenital disorders of the cerebellum such as ataxia telangiectasia [130], and in adult survivors of acquired childhood cerebellar tumors [131]. Adult patients with cerebellar degeneration have difficulty processing temporal regularities (although not tones) in music [132] and performing rhythmic movements [133].

## A Model of Cerebellar Motor Function in SBM

### The Cerebellum and Predictive Motor Control

A fundamental principle of neural computation is predictive processing that incorporates or generates information not only about past and present states but also about future states [134]. The idea that many brain functions are intrinsically predictive is in accord with the allocation of the brain's energy resources [135]. Predictive processes in motor control include an internal copy of the motor command and its predicted movement (the *efferece copy*) and a *corollary discharge*, the predicted sensory consequences of a motor command. The *residual error* is the difference between the predictive corollary discharge and the re-afferent sensory effects of the actual movement.

Predictive models have a number of putative functions [134], including distinguishing between internal and external events [136], estimating the current and future state of movement [137], rehearsing movements before carrying them out [138], increasing the salience of sensations with an external cause [139], overcoming time delays associated with feedback control [140–143], calibrating the correct body state needed for movement [144], and improving movement accuracy by forwarding sensory plans prior to movement [141].

Current models of the cerebellar role in motor function stress its role as a predictor of future timed movements and even as a general-purpose predictive controller [145]. As a result of movement experience, the cerebellum is argued to create internal sensory–motor representations that predict the consequences of motor plans or control the motor plans needed for a desired sensory outcome [146]. In Bastian's [147] model, the cerebellum adapts feed-forward control from one movement to the next by reducing errors in the feed-forward commands for subsequent movements.

Cerebellar agenesis is associated with severely disturbed predictive control of object grasp [148]. Adult onset cerebellar damage produces greater deficits on tasks requiring predictive rather than reactive control [147]; in contrast, individuals with basal ganglia disorders perform relatively well on predictive control tasks [149].

### Motor Function in SBM

Using the existing literature, we now develop a preliminary model of SBM motor function that attempts to account for the combination of intact and impaired motor skills and for the distinctive neuroanatomical features of the cerebellum in this disorder, and that attempts to generate specific predictions about motor functions as yet unstudied in SBM.

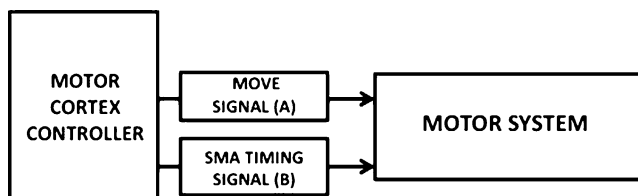
## Movement Programming

A controller in the motor cortex sends signals to the motor systems that effect movement. The move signal (A) includes movement parameters such as reach and force, and because timing is controlled separately from other movement parameters [150], we assume there to be a separate timing signal (B). The timing signal may be incorporated within the motor command discharge signal (i.e., the discharge rate or inter-discharge rate intervals, or frequency of discharge), but timing signals also originate in the supplementary motor area, SMA [151] (Fig. 2).

Some features of the move signal (A) must be intact in children with SBM. Typically, their saccades are accurately programmed [89], and when reaching to a target with the upper limb, they program movement parameters (e.g., both children with SBM and controls show a bell-shaped velocity curve scaled to target distances [55]). The timing signal (B) is inaccurate in children with SBM because of subsecond timing deficits [120].

### Cerebellar Calibration of Movement: Efference Copies, Corollary Discharge, and Predictive Timing

An efference copy forms input to a forward dynamic model (assumed to be in the lateral cerebellum [143]) that generates an internal state estimate within an internal cerebro-cerebellar feedback loop; the cerebellum then generates the corollary discharge. In children with SBM, we assume that the efference copies represent the move signal (C) more accurately than the timing signal (D). The decreased white matter integrity in the middle cerebellar peduncle in SBM [25] may also attenuate the signal from the motor cortex and SMA by disrupting the connection from the pons to the cerebellar cortex, in which case both move and timing signals might be suboptimal. Either way, the cerebellar input is defective, and the forward output model involving a corollary discharge (F) is an imperfect prediction of the timing (and perhaps movement) parameters of the action (Fig. 3).



**Fig. 2.** Motor model: movement programming. The move signal (A) includes movement parameters such as reach and force, and because timing is controlled separately from other movement parameters [141], we assume that there is a separate timing signal (B)

An entailment of the model is that individuals with SBM will create attenuated motor resonance, a form of efference copy. Brain regions active during action observation (e.g., of a hand action) are also active during understanding those actions, in an effector-dependent manner [152]. The referential motor resonance effect refers to a group of observations showing that the motor system simulates the action described in a statement [153]. In reading *close the drawer*, for example, it is faster to act moving away from the body than to act towards the body because the former is resonant with the action [154].

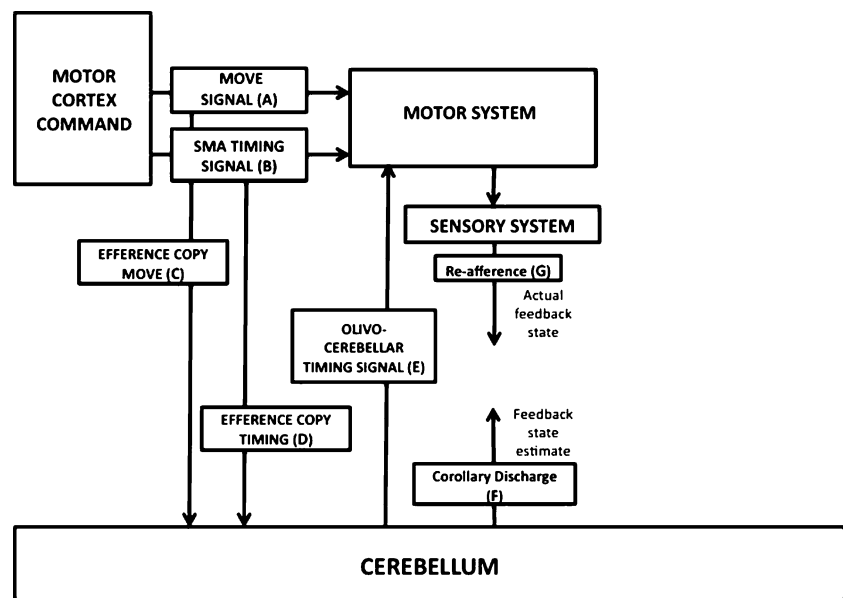
The predictive corollary discharge compensates for feedback delays in sensory–motor systems and feeds into the sensory pathway to cancel out re-afferent signals (G) generated by the actual movement [155] in instances in which it is important to distinguish self-generated and externally generated sources of stimulation [156]. Normally, being tickled by other people, where there are no efference copies of the movements, is subjectively more ticklish than tickling ourselves, where efference copies signal that we are tickling ourselves [136, 157]. When one finger touches the other, the sensation is weaker than the same stimulus externally imposed (a specific example of the general finding that the expected sensory consequences of self-generated movement are processed in attenuated form [158]), but the attenuation involves a predictive, not a reactive mechanism, because attenuation occurs even when the fingers unexpectedly fail to make contact [159].

Children with SBM may be less able to distinguish re-afference (sensory consequences of one’s own movement) from ex-afference (from external stimulation). They are reported to be excessively ticklish in response to routine tactile stimulation [53], suggesting failure to attenuate re-afference, or at least some incompatibility between re-afference and ex-afference. Because perception of the consequences of self-generated action is temporally tuned to the predicted action [160], children with SBM may be further compromised by timing deficits.

A further entailment of the model is that children with SBM will be less able than typically developing children to correctly assign induced movement errors to their source. In a study of how induced errors affect reaching, Diedrichsen et al. [161] found that people assign motor execution errors (mechanically perturbing the hand, or perturbing the visual feedback from a cursor representing the hand) to the movement, but target errors (moving the target) to external forces. Normally, only errors assigned to the movement lead individuals to make feed-forward corrections on the next movement, suggesting that arm perturbations are interpreted as arising from a faulty efference copy.

A predictive timing signal may also be the actual output of the inferior olive (IO) modulated by the cerebellar cortex because the olivo-cerebellar system generates temporal

**Fig. 3.** Motor model: cerebellar calibration of movement. Efference copies represent move signal (C) and timing signal (D). A predictive timing signal may also be the actual output of the inferior olive (E). A forward output model involves a corollary discharge (F), which compensates for feedback delays in sensory–motor systems, and feeds into the sensory pathway to cancel out re-afferent signals (G) generated by the actual movement



patterns in the inferior olive that are responsible for timing intervals on the order of hundreds of milliseconds using oscillations to keep track of time [162, 163]. Llinás et al. [164] have even suggested, “our motor timing is nothing other than the echo of our IO oscillation.” [p. 270]. An IO predictive timing signal (E) may be defective in SBM because of the irregular configuration of the olivary nuclei [165] and micropathology in climbing fibers from olivary nuclei [12] that interfere with generation of an accurate olivo-cerebellar timing signal.

#### Movement Errors, Motor Learning, Movement Performance, and New State Estimate

Adaptation, an error-based process of adjusting movements to new demands, involves an error cancellation process and a predictive calibration of movement for new task demands [166]. Within the cerebellum, simple spike activity may indicate both error detection and a predictive signal. During the initial learning of a new tool (a computer mouse with a novel rotational transformation), cerebellar activity is widespread during the initial learning and proportional to the errors, representing the error signal; after learning, activation persists in the posterior superior fissure, reflecting an acquired predictive model of the new tool use [167]. The cerebellar projection to the inferior parietal lobule may provide signals that contribute to or initiate the recalibration of the predictive model [168] (Fig. 4).

Movement errors can arise from a mismatch between predicted and actual movement (H). Correction of the movement error (I) facilitates both performance (K) and learning (J). Before a motor act is executed, an internalization of the movement is calibrated by visual information (L) about, for example, target and hand [55].

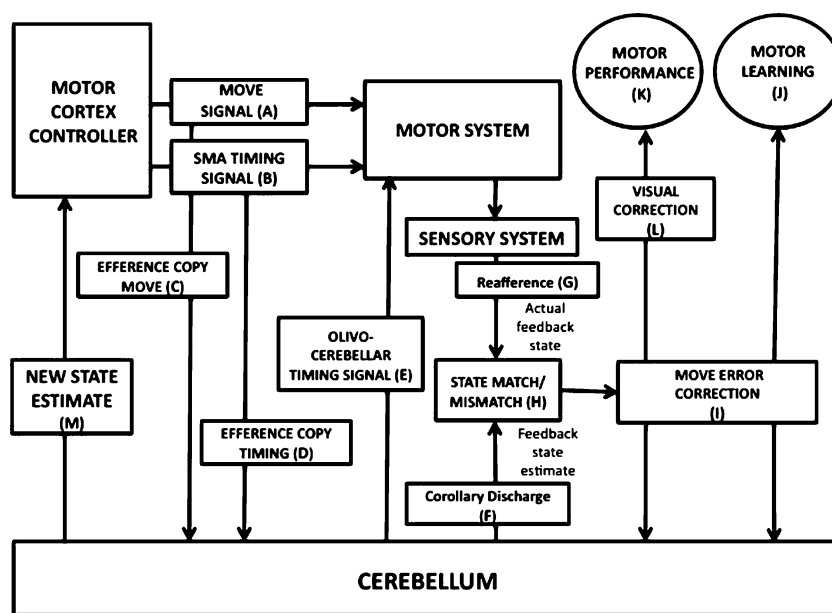
Individuals with SBM respond to movement errors, both those they monitor consciously (mirror drawing [103]; ballistic arm movements [105]) and those that occur too rapidly for conscious monitoring (saccadic adaptation [101]). They learn a range of movement tasks (J), although their error correction may be slower than that of controls [169].

Individuals with SBM perform poorly on tasks on which they exhibit intact learning (J vs. K). One reason may be that they are insensitive to visual calibration of the motor effector by external input (L). Performing a concurrent visual task affects visual sway in typically developing individuals but not in those with SBM [51]. Visual feedback improves reaching movements of typically developing individuals, but not those with SBM, whose performance even decreases with visual feedback (they show longer movement path durations and make more directional errors [55]). It seems reasonable to suppose, then, that the visual calibration of the motor effector (L) is impaired.

The model addresses the dissociation in SBM between different types of motor performance tasks. While upper limb movement in children with SBM is generally poor, they generally perform better on closed-loop motor tasks (such as ballistic arm movements to a visual target [105]) than on open-loop tasks requiring ongoing motor adjustments (e.g., mirror drawing [103]). Compared with open-loop tasks, closed-loop tasks involve precise timing parameters only at the beginning and end of the movement, not throughout, and do not require that one movement be informed by the movement dynamics of the previous movement. The performance of individuals with SBM improves with error-based corrections of the same movement (e.g., the elbow goniometer task [105]), but not when the



**Fig. 4.** Motor model: adaptation and learning. Movement errors can arise from a mismatch between predicted and actual movement (*H*). Correction of the movement error (*I*) facilitates both performance (*K*) and learning (*J*). Before a motor act is executed, an internalization of the movement is calibrated by visual information (*L*) for example, about target and hand



required movement changes from trial to trial (e.g., mirror drawing task [103]), which is in accord with the idea that they respond to an error signal but do not create a fully predictive model of the learned movement to calibrate ongoing, future movements [167]. The fact that the posterior parietal cortex is volumetrically thinner in SBM than in age peers [35] may further limit the recalibration of the predictive model of motor learning. The anterior cerebellum is a node in forms of motor control involving computing a predictive state estimator of one effector (e.g., the arm) to coordinate the actions of another effector (e.g., the fingers [170]). It will be important to understand whether and how the enhanced anterior cerebellum in SBM is related to motor learning.

During learning of a fixed sequence of movements, such as what occurs during the repeated tapping of a rhythmic pattern, entrainment of the rhythm occurs so that not only the movements but also their temporal pattern is learned. Such rhythms may assist the cortical motor networks to control automatic movements within chunks and the cognitive control networks to control non-automatic movements between chunks, allowing motor skills to be both automatic and flexible [171]. While children with SBM perform well on motor learning tasks, they fail to entrain rhythmic sequences [120].

The model accommodates the dissociation in SBM between deficient motor timing and intact motor adaptation and learning. While it has been proposed that timing and motor learning have a common basis in the granular layer of the cerebellum [172], it is the case, as here, that the functions can be somewhat dissociated.

The cerebellum provides feed-forward information to the motor controller in the form of a new state estimate (*M*). It is possible that the feedback from the cerebellum to the motor

cortex is selectively poor for timing in SBM; anatomically, at least, the cerebello-cerebral feedback circuit is different for movement parameters (through the motor thalamus to the motor cortex) than for timing parameters (through the intralaminar nonspecific thalamic nuclei to the SMA [71]). In addition, feed-forward information involves a remapping of peripersonal space, that part of egocentric space within an arm's reach that is used for activities like picking up objects or drawing [173], and which plays a role in the motor control of voluntary actions [174]. Peripersonal space develops atypically in children with SBM, who differ from their age peers in terms of an exaggerated attentional bias to left hemispace, an abnormal attentional bias to inferior hemispace, and an enhanced Weber fraction, a larger zone of subjective uncertainty about peripersonal space [175]. In SBM, peripersonal spatial deficits may be both a cause and an effect of poor movement regulation.

## Discussion

Individuals with SBM have widespread motor deficits that are broadly congruent with function and neuroanatomy of damage in adult cerebellar lesions. In lesioned adults, the posterior vermis produces truncal ataxia and oculomotor problems and the intermediate parasagittal and lateral zones produce limb ataxia and dysarthria. There is also a pattern of enlarged anterior vermis and attenuated posterior vermis and lateral zones (to be sure, many correlations of volumetrics and specific functions have yet to be made). Error-based motor learning is generally intact in SBM, although a full predictive signal that includes the temporal features of movement is impoverished, which likely

contributes to deficits in smooth movement coordination as well as to the classical cerebellar triad of dysmetria, ataxia, and dysarthria. That motor function in SBM is disordered in a manner phenotypically like that in adult cerebellar lesions, and appears to involve similar deficits in predictive cerebellar motor control, suggests that age-based cerebellar motor plasticity is limited in individuals with this neurodevelopmental disorder. Thus, children with SBM have cerebellar motor deficits that are consistent with motor deficits that follow adult cerebellar lesions; the cerebellar motor profile of SBM is distinctive in that it appears to permit motor learning but not predictive motor control.

Cerebellar dysmorphologies and dysfunction occur in many neurodevelopmental disorders [176], including rare disorders like cerebellar agenesis, Dandy Walker syndrome, and Joubert syndrome, as well as more prevalent disorders like cerebral palsy in which cerebellar impairment is part of a broader motor disorder. Striving for a better delineation of cerebellar motor function in neurodevelopmental disorders, and generating specific, testable predictions about performance on experimental motor paradigms to emend and amplify the preliminary motor model, will enhance understanding of the individual conditions. In addition, such delineations will also identify putative common principles of cerebellar motor function that can then be compared across neurodevelopmental disorders involving the cerebellum, childhood-acquired cerebellar disorders, and adult cerebellar lesions.

Other forms of neuropathology in SBM affect cognitive function, many originating in the events following the Chiari II. The presence of other neuropathology is not unusual for disorders involving the cerebellum. Of adult patients preselected to have isolated cerebellar lesions from diverse etiologies (infarcts, tumors, and arteriovenous malformation), 77% have supratentorial perfusional deficits on SPECT [177]. In SBM, extracerebellar pathologies are part of a causative developmental chain of neuropathological events initiated by the expansion failure of the embryonic vesicles and a small posterior fossa and abnormal cerebellum. The effects of cerebellar damage appear to produce deficits in specific cerebellar functions, not simply a pattern of globally impaired motor functions. Some extracerebellar damage in SBM has been related to cognitive functions like attention, rather than to cerebellar motor function. In SBM, mechanical effects on the midbrain of cerebellar deformities, where the midbrain tectum is pushed into a beak, are associated with deficits in attention orienting and disengagement [178]. Other forms of extracerebellar damage in SBM, such as corpus callosum agenesis and hypoplasia, are related to cognitive functions and are demonstrably unrelated to the state of the cerebellum in the same individuals [179]. While functional impairments in a range of cognitive domains in SBM may be exacerbated by other neuroanatomical anomalies, including beaking of the midbrain tectum [180], volume reduction in the posterior

parietal lobe [35], and compromised white matter in association tracts [181], cerebellar and extracerebellar pathologies in SBM appear to account for different functions.

Emerging evidence highlights the cerebellum as an important node in the distributed neural circuits subserving cognition as well as movement [182]. Here, we advance the general hypothesis that the motor deficits involving the upper and lower limbs, which are present at birth and likely affect the long-term development of a range of cognitive functions, represent not only orthopedic and movement difficulties but also an imperfect substrate for long-term neurocognitive development. Specifically, we argue that:

1. Formative cerebellar pathologies in SBM produce cerebellar motor defects involving deficient feed-forward control. Failure of predictive motor control produces ataxia and dysmetria in many individuals with SBM, representing the execution of movements without the calibrating benefits of previous experience accumulated through learning and emergent rhythm patterns [141].
2. Predictive models for motor control may shape cognition [146], specifically, predicting movement outcomes and understanding the meaning of movements, now termed *motor cognition* [183]. In SBM, deficient motor development from birth fails to scaffold important aspects of later cognitive development so that the acquisition of particular cognitive domains will be shaped by the motor deficits. For example, the physical act of reaching creates a constant remapping of peripersonal space, which in turn is the platform for development of primitive quantity relations like *bigger* and *smaller* [184]. Children with SBM have poor predictive reaching, a less articulated peripersonal space [175], and even as toddlers, a poorer grasp of quantitative relations [36]. Although not yet studied in SBM, failure to represent other people's movements may be the basis of poor social cognition [185]. In this context, it is interesting that the cerebellum is activated not only during speech production but also by instructions to *imagine* speaking [186].
3. Providing targeted therapies to facilitate movement at a very early age in children with SBM and other neurodevelopmental disorders may not only facilitate motor development but also exert a broader positive effect on other outcome domains. This hypothesis is congruent with recent observations that in typically developing preschool children, induced movement patterns dictate with some specificity the way their brains are structured to learn [187].
4. In SBM, a fundamental failure of feed-forward processing may be common to movement and cognition. In other contexts, we have argued that SBM impair-

ments within and across cognitive content domains represent problems in iterative integration of old and new information by means of feed-forward mental models [36, 188, 189].

SBM is a strong model of the effects of cerebellar pathology on motor functions, deficits in which may fail to scaffold aspects of cognitive development. Our general hypothesis about neurocognitive function in SBM is that primary cerebellar motor deficits, particularly those involving failure of feed-forward processing, are linked to later impairments in spatial attention, peripersonal space, language comprehension, mathematics, and possibly social cognition. What we do not yet know is whether cognitive processing is shaped by the effects of motor deficits or caused by a failure of feed-forward processing common to movement and cognition. Theoretically based research on movement across neurodevelopmental disorders may illuminate exactly how cognitive development is grounded in how we learn to move.

**Acknowledgement** Preparation of this paper was supported in part by grant P01-HD35946 awarded from the Eunice Kennedy Shriver National Institute of Child Health and Human Development (NICHD). The content is solely the responsibility of the authors and does not necessarily represent the official views of the NICHD or the National Institutes of Health. We thank Alexandra Basile for assistance with the preparation of the manuscript.

**Conflict of interest statement** There are no financial or personal relationships that might bias this work (e.g., consultancies, stock ownership, equity interests, and patent-licensing arrangements). No conflicts of interest exist.

## References

- Boulet SL, Gambrell D, Shin M, Honein MA, Mathews TJ. Racial/ethnic differences in the birth prevalence of spina bifida—United States, 1995–2005. *JAMA*. 2009;301(21):2203–4.
- Koehler PJ, De Wever Z, Heerlen G. Neurology in Tulp's observationes medicae. *J Hist Neurosci*. 1996;5:143–51.
- Lendon RG. Neuron population in the lumbosacral cord of myelomeningocele children. *Dev Med Child Neurol Suppl*. 1969;20:82–5.
- Lendon RG. Neuron population in the spinal cord of children with spina bifida and hydrocephalus. *Dev Med Child Neurol*. 1968;10(s15):50–4.
- McEnery G, Borzyskowski M, Cox TC, Neville BG. The spinal cord in neurologically stable spina bifida: a clinical and MRI study. *Dev Med Child Neurol*. 1992;34(4):342–7.
- Cleland J. Contributions to the study of spina bifida, encephalocoele, and anencephalus. *J Anat Physiol*. 1883;17:257–91.
- Arnett B. Arnold–Chiari malformation. *Arch Neurol*. 2003;60(6):898–900.
- Pearce JMS. Arnold Chiari, or “Cruveilhier Cleland Chiari” malformation. *J Neurol Neurosurg Psychiatry*. 2000;68(1):8–13.
- Wagner WA, Schwarz MA, Perneczky AB. Primary myelomeningocele closure and consequences. *Curr Opin Urol*. 2002;12(6):465–8.
- Barkovich AJ. *Pediatric neuroimaging*. 3rd ed. New York: Raven; 2000.
- Harding B, Copp A. Malformations. In: Graham D, Lantos P, editors. *Greenfield's neuropathology*. London: Edward Arnold; 2002. p. 376–86.
- Gilbert J, Jones K, Rorke L, Chemoff G, James H. Central nervous system anomalies associated with meningomyelocele, hydrocephalus, and the Arnold–Chiari malformation: reappraisal of theories regarding the pathogenesis of posterior neural tube closure defects. *Neurosurgery*. 1986;18:559–64.
- Hannay HJ, Dennis M, Kramer L, Blaser S, Fletcher JM. Partial agenesis of the corpus callosum in spina bifida meningomyelocele and potential compensatory mechanisms. *J Clin Exp Neuropsychol*. 2009;31(2):180–94.
- McLone DG, Dias MS. The Chiari II malformation: cause and impact. *Childs Nerv Syst*. 2003;19(7):540–50.
- McLone DG, Knepper PA. The cause of Chiari II malformation: a unified theory. *Pediatr Neurosci*. 1989;15:1–12.
- Bruner JP, Tulipan N, Paschall RL, Boehm FH, Walsh WF, Silva SR, et al. Fetal surgery for myelomeningocele and the incidence of shunt-dependent hydrocephalus. *JAMA*. 1999;282(19):1819–25.
- Danzer E, Johnson M, Bebbington M, Simon E, Wilson R, Bilaniuk L, et al. Fetal head biometry assessed by fetal magnetic resonance imaging following in utero myelomeningocele repair. *Fetal Diagn Ther*. 2007;22(1):1–6.
- Sutton LN, Adzick NS, Bilaniuk LT, Johnson MP, Crombleholme TM, Flake AW. Improvement in hindbrain herniation demonstrated by serial fetal magnetic resonance imaging following fetal surgery for myelomeningocele. *JAMA*. 1999;282(19):1826–31.
- Danzer E, Finkel RS, Rintoul NE, Bebbington MW, Schwartz ES, Zarnow DM, et al. Reversal of hindbrain herniation after maternal–fetal surgery for myelomeningocele subsequently impacts on brain stem function. *Neuropediatrics*. 2008;39(06):359–62.
- Boltshauser E, Schneider J, Kollias S, Waibel P, Weissert M. Vanishing cerebellum in myelomeningocele. *Eur J Paediatr Neurol*. 2002;6(2):109–13.
- Emery JL, Gadsdon DR. A quantitative study of the cell population of the cerebellum in children with myelomeningocele. *Dev Med Child Neurol Suppl*. 1975;35:20–5.
- Salman MS, Blaser SE, Sharpe JA, Dennis M. Cerebellar vermiform morphology in children with spina bifida and Chiari type II malformation. *Childs Nerv Syst*. 2006;22(4):385–93.
- Tsai T, Bookstein FL, Levey E, Kinsman SL. Chiari-II malformation: a biometric analysis. *Eur J Pediatr Surg*. 2002;12(S1):12–8.
- Juranek J, Dennis M, Cirino PT, El-Messidi L, Fletcher JM. The cerebellum in children with spina bifida and Chiari II malformation: quantitative volumetrics by region. *Cerebellum*. 2010;9(2):240–8.
- Herweh C, Akbar M, Wengenroth M, Heiland S, Bendszus M, Stippich C. Reduced anisotropy in the middle cerebellar peduncle in Chiari-II malformation. *Cerebellum*. 2010 (in press).
- Harding BN, Copp AJ, editors. *Malformations*. 8th ed. London: Hodder Arnold; 2008.
- Sav A. Pathological anatomy of spina bifida. In: Ozek MM, Cinalli G, Maixner W, editors. *The spina bifida management and outcome*. Milan: Springer; 2008.
- Variend S, Emery JL. The pathology of the central lobes of the cerebellum in children with myelomeningocele. *Dev Med Child Neurol*. 1974;16(6 Suppl 32):99–106.
- Kuchukhidze G, Rauchenzauner M, Gotwald T, Janecke A, Trinka E. Hypoplasia of deep cerebellar nuclei in Joubert Syndrome. *Pediatr Neurol*. 2009;40(6):474–6.
- Baumel Y, Jacobson GA, Cohen D. Implications of functional anatomy on information processing in the deep cerebellar nuclei. *Frontiers in Cellular Neuroscience*. 2009;3:14. doi:10.3389/neuro.03.014.2009.
- Griffiths P, Wilkinson I, Variend S, Jones A, Paley M, Whitby E. Differential growth rates of the cerebellum and posterior fossa

- assessed by post mortem magnetic resonance imaging of the fetus: implications for the pathogenesis of the Chiari 2 deformity. *Acta Radiol.* 2004;45(2):236–42.
32. Raybaud C, Miller E. Radiological evaluation of myelomeningocele—Chiari II malformation. In: Ozek M, Cinalli G, Maixner W, editors. *Spina bifida: management and outcome*. Milan: Springer; 2008. p. 111–42.
  33. Juranek J, Salman MS. Anomalous development of brain structure and function in spina bifida myelomeningocele. *Developmental Disorders and Research Reviews.* 2010;16:23–30.
  34. Dennis M, Fitz C, Netley C, Sugar J, Harwood-Nash D, Hendrick E, et al. The intelligence of hydrocephalic children. *Arch Neurol.* 1981;38(10):607–15.
  35. Juranek J, Fletcher JM, Hasan KM, Breier JI, Cirino PT, Pazo-Alvarez P, et al. Neocortical reorganization in spina bifida. *Neuroimage.* 2008;40(4):1516–22.
  36. Dennis M, Barnes MA. The cognitive phenotype of spina bifida meningocele. *Dev Disabil Res Rev.* 2010;16(1):31–9.
  37. Del Bigio MR. Neuropathology and structural changes in hydrocephalus. *Dev Disabil Res Rev.* 2010;16(1):16–22.
  38. Warrington WB, Monsarrat K. A case of arrested development of the cerebellum and its peduncles with spina bifida and other developmental peculiarities in the cord. *Brain.* 1902;25:444–78.
  39. Turnbull FA. Syringomyelic complications of spina bifida. *Brain.* 1933;56:304–17.
  40. Schwartz ER. Characteristics of speech and language development in the child with myelomeningocele and hydrocephalus. *J Speech Hear Disord.* 1974;39:465–8.
  41. Magnus JA. Congenital paralysis of both external recti treated by transplantation of eye muscles. *Br J Ophthalmol.* 1944;28(5):241–5.
  42. Ivory RB, Richardson TC. Temporal control and coordination: the multiple timer model. *Brain Cogn.* 2002;48(1):117–32.
  43. Combe G. *On the functions of the cerebellum*. London: Maclachlan & Stewart; 1838.
  44. Babinski J. Sur le rôle du cervelet dans les actes volitionnels nécessitant une succession rapide de mouvements. *Revue Neurologique.* 1902;10:1013–5.
  45. Holmes G. The cerebellum of man. *Brain.* 1939;62:1–30.
  46. Williams EN, Broughton NS, Menelaus MB. Age-related walking in children with spina bifida. *Dev Med Child Neurol.* 1999;41(7):446–9.
  47. Wallace SJ. The effect of upper-limb function on mobility of children with myelomeningocele. *Dev Med Child Neurol Suppl.* 1973;Suppl 29:84–91.
  48. Karlsson A, Norrlin S, Silander HC, Dahl M, Lanshammar H. Amplitude and frequency analysis of force plate data in sitting children with and without MMC. *Clin Biomech (Bristol, Avon).* 2000;7:541–5.
  49. Norrlin S, Karlsson A, Ahlsten G, Lanshammar H, Silander HC, Dahl M. Force measurements of postural sway and rapid arm lift in seated children with and without MMC. *Clin Biomech (Bristol, Avon).* 2002;3:197–202.
  50. Dennis M, Salman MS, Jewell D, Hetherington R, Spiegler BJ, MacGregor DL, et al. Upper limb motor function in young adults with spina bifida and hydrocephalus. *Childs Nerv Syst.* 2009;25(11):1447–53.
  51. Høglund A, Norrlin S. Influence of dual tasks on sitting postural sway in children and adolescents with myelomeningocele. *Gait Posture.* 2009;30(4):424–30.
  52. Jewell D, Fletcher JM, Mahy CE, Hetherington R, MacGregor D, Drake JM, et al. Upper limb cerebellar motor function in children with spina bifida. *Childs Nerv Syst.* 2010;26(1):67–73.
  53. Grimm RA. Hand function and tactile perception in a sample of children with myelomeningocele. *Am J Occup Ther.* 1976;30(4):234–40.
  54. Muen WJ, Bannister CM. Hand function in subjects with spina bifida. *Eur J Pediatr Surg.* 1997;7 Suppl 1:18–22.
  55. Norrlin S, Dahl M, Rosblad B. Control of reaching movements in children and young adults with myelomeningocele. *Dev Med Child Neurol.* 2004;46(1):28–33.
  56. Fletcher J, Brookshire B, Bohan T, Brandt M, Davidson K. Early hydrocephalus. In: Rourke B, editor. *Syndrome of nonverbal learning disabilities: neurodevelopmental manifestations*. New York: Guilford; 1995. p. 206–38.
  57. Hetherington R, Dennis M. Motor function profile in children with early onset hydrocephalus. *Dev Neuropsychol.* 1999;15(1):25–51.
  58. Lomax-Bream LE, Barnes M, Copeland K, Taylor HB, Landry SH. The impact of spina bifida on development across the first 3 years. *Dev Neuropsychol.* 2007;31(1):1–20.
  59. Vinck A, Nijhuis-van der Sanden MW, Roeleveld NJ, Mullaart RA, Rotteveel JJ, Maassen BA. Motor profile and cognitive functioning in children with spina bifida. *Eur J Paediatr Neurol.* 2010;14(1):86–92.
  60. Wills K. Neuropsychological functioning in children with spina bifida and/or hydrocephalus. *J Clin Child Psychol.* 1993;22(2):247–65.
  61. Zeiner HK, Prigatano GP, Pollay M, Biscoe CB, Smith RV. Ocular motility, visual acuity and dysfunction of neuropsychological impairment in children with shunted uncomplicated hydrocephalus. *Childs Nerv Syst.* 1985;1(2):115–22.
  62. Anderson EM, Plewis I. Impairment of a motor skill in children with spina bifida cystica and hydrocephalus: an exploratory study. *Br J Psychol.* 1977;68(1):61–70.
  63. Hamilton A, Shah A. Physical hand function of the child with spina bifida-myelomeningocele. *British Journal of Occupational Therapy.* 1984;147–50.
  64. Turner A. Hand function in children with myelomeningocele. *J Bone Joint Surg Br.* 1985;67(2):268–72.
  65. Turner A. Upper-limb function of children with myelomeningocele. *Dev Med Child Neurol.* 1986;28(6):790–8.
  66. Brunt D. Characteristics of upper limb movements in a sample of meningocele children. *Percept Mot Skills.* 1980;51(2):431–7.
  67. Sandler AD, Macias M, Brown TT. The drawings of children with spina bifida: developmental correlations and interpretations. *Eur J Pediatr Surg.* 1993;3 Suppl 1:25–7.
  68. Soare P, Raimondi A. Intellectual and perceptual-motor characteristics of treated myelomeningocele children. *Am J Dis Child.* 1977;131(2):199–204.
  69. Pearson A, Carr J, Hallwell M. The handwriting of children with spina bifida. *Z Kinderchir.* 1988;43(S2):40–2.
  70. Ziviani J, Hayes A, Chant D. Handwriting: a perceptual-motor disturbance in children with myelomeningocele. *Occup Ther J Res.* 1990;10:12–26.
  71. Blumenfeld H. *Neuroanatomy through clinical cases*. Sunderland: Sinauer; 2002.
  72. Brown JR, Darley FL, Aronson AE. Ataxic dysarthria. *Int J Neurol.* 1970;7(2):302–18.
  73. Darley FL, Aronson AE, Brown JR. Differential diagnostic patterns of dysarthria. *J Speech Hear Res.* 1969;12(2):246–69.
  74. Dennis M, Hendrick EB, Hoffman HJ, Humphreys RP. Language of hydrocephalic children and adolescents. *J Clin Exp Neuropsychol.* 1987;9(5):593–621.
  75. Huber-Okraïnc J, Dennis M, Bretschneider J, Spiegler BJ. Neuromotor speech deficits in children and adults with spina bifida and hydrocephalus. *Brain Lang.* 2002;80(3):592–602.
  76. Kent RD, Netsell R, Abbs JH. Acoustic characteristics of dysarthria associated with cerebellar disease. *J Speech Hear Res.* 1979;22(3):627–48.

77. Ackermann H, Mathiak K, Ivry RB. Temporal organization of “internal speech” as a basis for cerebellar modulation of cognitive functions. *Behav Cogn Neurosci Rev.* 2004;3(1):14–22.
78. Caines E, Dahl M, Holmstrom G. Longterm oculomotor and visual function in spina bifida cystica: a population-based study. *Acta Ophthalmol Scand.* 2007;85(6):662–6.
79. Nishizaki T, Tamaki N, Nishida Y, Matsumoto S. Bilateral internuclear ophthalmoplegia due to hydrocephalus: a case report. *Neurosurgery.* 1985;17(5):822–5.
80. Arnold AC, Baloh RW, Yee RD, Hepler RS. Internuclear ophthalmoplegia in the Chiari type II malformation. *Neurology.* 1990;40(12):1850–4.
81. Biglan AW. Ophthalmologic complications of meningocele: a longitudinal study. *Trans Am Ophthalmol Soc.* 1990;88:389–462.
82. Collard M, Strubel-Streicher D, Eber AM, Remy C. Oculomotor disorders associated with Arnold–Chiari malformations (author’s transl). *Rev Neurol (Paris).* 1980;136(8–9):531–8.
83. Leigh R, Zee D. *The neurology of eye movements.* 4th ed. New York: Oxford University Press; 2006.
84. Lennerstrand G, Gallo J, Samuelsson L. Neuro-ophthalmological findings in relation to CNS lesions in patients with myelomeningocele. *Dev Med Child Neurol.* 1990;32(5):423–31.
85. Lennerstrand G, Gallo J. Neuro-ophthalmological evaluation of patients with myelomeningocele and Chiari malformations. *Dev Med Child Neurol.* 1990;32(5):415–22.
86. Longridge NS, Mallinson AI. Arnold–Chiari malformation and the otolaryngologist: place of magnetic resonance imaging and electronystagmography. *Laryngoscope.* 1985;95(3):335–9.
87. Mossman SS, Bronstein AM, Gresty MA, Kendall B, Rudge P. Convergence nystagmus associated with Arnold–Chiari malformation. *Arch Neurol.* 1990;47(3):357–9.
88. Spooner JW, Baloh RW. Arnold–Chiari malformation: improvement in eye movements after surgical treatment. *Brain.* 1981;104(Pt 1):51–60.
89. Salman MS, Sharpe JA, Eizenman M, Lillakas L, To T, Westall C, et al. Saccades in children with spina bifida and Chiari type II malformation. *Neurology.* 2005;64(12):2098–101.
90. Salman MS, Sharpe JA, Lillakas L, Dennis M, Steinbach MJ. The vestibulo-ocular reflex during active head motion in Chiari II malformation. *Can J Neurol Sci.* 2008;35(4):495–500.
91. Salman MS, Sharpe JA, Lillakas L, Dennis M, Steinbach MJ. Visual fixation in Chiari type II malformation. *J Child Neurol.* 2009;24(2):161–5.
92. Salman MS, Sharpe JA, Lillakas L, Steinbach MJ, Dennis M. Smooth ocular pursuit in Chiari type II malformation. *Dev Med Child Neurol.* 2007;49(4):289–93.
93. Takagi M, Zee DS, Tamargo RJ. Effects of lesions of the oculomotor vermis on eye movements in primate: saccades. *J Neurophysiol.* 1998;80(4):1911–31.
94. Fukushima K, Buharin EV, Fukushima J. Responses of floccular Purkinje cells to sinusoidal vertical rotation and effects of muscimol infusion into the flocculus in alert cats. *Neurosci Res.* 1993;17(4):297–305.
95. Yakusheva TA, Shaikh AG, Green AM, Blazquez PM, Dickman JD, Angelaki DE. Purkinje cells in posterior cerebellar vermis encode motion in an inertial reference frame. *Neuron.* 2007;54(6):973–85.
96. Desmurget M, Pelisson D, Grethe JS, Alexander GE, Urquizar C, Prablanc C, et al. Functional adaptation of reactive saccades in humans: a PET study. *Exp Brain Res.* 2000;132(2):243–59.
97. Barash S, Melikyan A, Sivakov A, Zhang M, Glickstein M, Thier P. Saccadic dysmetria and adaptation after lesions of the cerebellar cortex. *J Neurosci.* 1999;19(24):10931–9.
98. Vaziri S, Diedrichsen J, Shadmehr R. Why does the brain predict sensory consequences of oculomotor commands? Optimal integration of the predicted and the actual sensory feedback. *J Neurosci.* 2006;26(16):4188–97.
99. Baier B, Stoeter P, Dieterich M. Anatomical correlates of ocular motor deficits in cerebellar lesions. *Brain.* 2009;132(Pt 8):2114–24.
100. Salman MS, Dennis M, Sharpe JA. The cerebellar dysplasia of Chiari II malformation as revealed by eye movements. *Can J Neurol Sci.* 2009;36(6):713–24.
101. Salman MS, Sharpe JA, Eizenman M, Lillakas L, To T, Westall C, et al. Saccadic adaptation in Chiari type II malformation. *Can J Neurol Sci.* 2006;33(4):372–8.
102. Colvin AN, Yeates KO, Enrile BG, Coury DL. Motor adaptation in children with myelomeningocele: comparison to children with ADHD and healthy siblings. *J Int Neuropsychol Soc.* 2003;9(04):642–52.
103. Edelman K, Dennis M, Copeland K, Frederick J, Francis D, Hetherington R, et al. Motor learning in children with spina bifida: dissociation between performance level and acquisition rate. *J Int Neuropsychol Soc.* 2004;10(6):877–87.
104. Wiedenbauer G, Jansen-Osmann P. Mental rotation ability of children with spina bifida: what influence does manual rotation training have? *Dev Neuropsychol.* 2007;32(3):809–24.
105. Dennis M, Jewell D, Edelman K, Brandt ME, Hetherington R, Blaser SE, et al. Motor learning in children with spina bifida: intact learning and performance on a ballistic task. *J Int Neuropsychol Soc.* 2006;12(5):598–608.
106. Albus JS. A theory of cerebellar function. *Math Biosci.* 1971;10:25–61.
107. Marr D. A theory of cerebellar cortex. *J Physiol.* 1969;202(2):437–70.
108. Weiner MJ, Hallett M, Funkenstein HH. Adaptation to lateral displacement of vision in patients with lesions of the central nervous system. *Neurology.* 1983;33(6):766–72.
109. Deuschl G, Toro C, Zeffiro T, Massaquoi S, Hallett M. Adaptation motor learning of arm movements in patients with cerebellar disease. *J Neurol Neurosurg Psychiatry.* 1996;60(5):515–9.
110. Doyon J, Benali H. Reorganization and plasticity in the adult brain during learning of motor skills. *Curr Opin Neurobiol.* 2005;15(2):161–7.
111. Doyon J, Penhune V, Ungerleider LG. Distinct contribution of the cortico-striatal and cortico-cerebellar systems to motor skill learning. *Neuropsychologia.* 2003;41(3):252–62.
112. Doyon J, Ungerleider LG. Functional anatomy of motor skill learning. In: Squire LR, Schacter DL, editors. *The neuropsychology of memory.* 3rd ed. New York: Guilford; 2002. p. 225–38.
113. Park J-W, Kim Y-H, Jang SH, Chang WH, C-h P, Kim ST. Dynamic changes in the cortico-subcortical network during early motor learning. *NeuroRehabilitation.* 2010;26(2):95–103.
114. Orban P, Peigneux P, Lungu O, Albouy G, Breton E, Laberrene F, et al. The multifaceted nature of the relationship between performance and brain activity in motor sequence learning. *Neuroimage.* 2010;49(1):694–702.
115. Hasan KM, Sankar A, Halphen C, Kramer LA, Ewing-Cobbs L, Dennis M, et al. Quantitative diffusion tensor imaging and intellectual outcomes in spina bifida: laboratory investigation. *J Neurosurg Pediatr.* 2008;2(1):75–82.
116. Werner S, Bock O, Gizewski ER, Schoch B, Timmann D. Visuomotor adaptive improvement and aftereffects are impaired differentially following cerebellar lesions in SCA and PICA territory. *Exp Brain Res.* 2010;201(3):429–39.
117. Lewis PA, Miall RC. Distinct systems for automatic and cognitively controlled time measurement: evidence from neuroimaging. *Curr Opin Neurobiol.* 2003;13(2):250–5.
118. Krumhansl CL. Rhythm and pitch in music recognition. *Psychol Bull.* 2000;126(1):159–79.



119. Griffiths TD. The neural processing of complex sounds. *Ann NY Acad Sci.* 2001;930:133–42.
120. Dennis M, Edelman K, Hetherington R, Copeland K, Frederick J, Blaser SE, et al. Neurobiology of perceptual and motor timing in children with spina bifida in relation to cerebellar volume. *Brain.* 2004;127(6):1292–301.
121. Dennis M, Hopyan T, Juraneck J, Cirino PT, Hasan KM, Fletcher J. Strong-meter and weak-meter rhythm identification in spina bifida meningomyelocele and volumetric parcellation of rhythm-relevant cerebellar regions. *Ann NY Acad Sci.* 2009;1169:84–8.
122. Hopyan T, Schellenberg EG, Dennis M. Perception of strong-meter and weak-meter rhythms in children with spina bifida meningomyelocele. *J Int Neuropsychol Soc.* 2009;15(4):521–8.
123. Kotani S, Kawahara S, Kirino Y. Purkinje cell activity during learning a new timing in classical eyeblink conditioning. *Brain Res.* 2003;994(2):193–202.
124. Koekkoek SK, Hulscher HC, Dortland BR, Hensbroek RA, Elgersma Y, Ruigrok TJ, et al. Cerebellar LTD and learning-dependent timing of conditioned eyelid responses. *Science.* 2003;301(5640):1736–9.
125. Braitenberg V. Is the cerebellar cortex a biological clock in the millisecond range? *Prog Brain Res.* 1967;25:334–46.
126. Ivry RB. The representation of temporal information in perception and motor control. *Curr Opin Neurobiol.* 1996;6(6):851–7.
127. Molinari M, Leggio MG, Thaut MH. The cerebellum and neural networks for rhythmic sensorimotor synchronization in the human brain. *Cerebellum.* 2007;6(1):18–23.
128. Ivry RB, Keele SW. Timing functions of the cerebellum. *J Cogn Neurosci.* 1989;1:136–52.
129. Ivry RB, Keele SW, Diener HC. Dissociation of the lateral and medial cerebellum in movement timing and movement execution. *Exp Brain Res.* 1988;73(1):167–80.
130. Mostofsky SH, Kunze JC, Cutting LE, Lederman HM, Denckla MB. Judgment of duration in individuals with ataxia-telangiectasia. *Dev Neuropsychol.* 2000;17(1):63–74.
131. Hetherington R, Dennis M, Spiegler B. Perception and estimation of time in long-term survivors of childhood posterior fossa tumors. *J Int Neuropsychol Soc.* 2000;6(6):682–92.
132. Lebrun-Guillaud G, Tillmann B, Justus T. Perception of tonal and temporal structures in chord sequences by patients with cerebellar damage. *Music Percept.* 2008;25:271–83.
133. Schlerf JE, Spencer RM, Zelaznik HN, Ivry RB. Timing of rhythmic movements in patients with cerebellar degeneration. *Cerebellum.* 2007;6(3):221–31.
134. Bubic A, von Cramon DY, Schubotz RI. Prediction, cognition and the brain. *Frontiers in Human Neuroscience.* 2010;4:1–15.
135. Raichle ME. Two views of brain function. *Trends Cogn Sci.* 2010;14(4):180–90.
136. Blakemore SJ, Wolpert DM, Frith CD. Central cancellation of self-produced tickle sensation. *Nat Neurosci.* 1998;1(7):635–40.
137. Wolpert DM, Miall RC. Forward models for physiological motor control. *Neural Netw.* 1996;9(8):1265–79.
138. Gross L. Self-generated touch: a neural perspective. *PLoS Biol.* 2006;4(2):e48.
139. Sperry RW. Neural basis of the spontaneous optokinetic response produced by visual inversion. *J Comp Physiol Psychol.* 1950;43(6):482–9.
140. Kawato M, Kuroda T, Imamizu H, Nakano E, Miyauchi S, Yoshioka T. Internal forward models in the cerebellum: fMRI study on grip force and load force coupling. *Prog Brain Res.* 2003;142:171–88.
141. Mauk MD, Medina JF, Noes WL, Ohyama T. Cerebellar function: coordination, learning or timing? *Curr Biol.* 2000;10(14):R522–5.
142. Pollok B, Gross J, Kamp D, Schnitzler A. Evidence for anticipatory motor control within a cerebello-diencephalic-parietal network. *J Cogn Neurosci.* 2008;20(5):828–40.
143. Wolpert DM, Miall RC, Kawato M. Internal models in the cerebellum. *Trends Cogn Sci.* 1998;2(9):338–47.
144. Molinari M, Restuccia D, Leggio MG. State estimation, response prediction, and cerebellar sensory processing for behavioral control. *Cerebellum.* 2009;8(3):399–402.
145. McKinstry JL, Edelman GM, Krichmar JL. A cerebellar model for predictive motor control tested in a brain-based device. *Proc Natl Acad Sci USA.* 2006;103(9):3387–92.
146. Iacoboni M. Playing tennis with the cerebellum. *Nat Neurosci.* 2001;4(6):555–6.
147. Bastian AJ. Learning to predict the future: the cerebellum adapts feedforward movement control. *Curr Opin Neurobiol.* 2006;16(6):645–9.
148. Nowak DA, Timmann D, Hermsdörfer J. Dexterity in cerebellar agenesis. *Neuropsychologia.* 2007;45(4):696–703.
149. Bares M, Lungu OV, Husarova I, Gescheidt T. Predictive motor timing performance dissociates between early diseases of the cerebellum and Parkinson's disease. *Cerebellum.* 2010;9(1):124–35.
150. Torres E, Andersen R. Space-time separation during obstacle-avoidance learning in monkeys. *J Neurophysiol.* 2006;96(5):2613–32.
151. Thaut MH, Demartin M, Sanes JN. Brain networks for integrative rhythm formation. *PLoS ONE.* 2008;3(5):e2312.
152. Aziz-Zadeh L, Wilson SM, Rizzolatti G, Iacoboni M. Congruent embodied representations for visually presented actions and linguistic phrases describing actions. *Curr Biol.* 2006;16(18):1818–23.
153. Fischer MH, Zwaan RA. Embodied language: a review of the role of the motor system in language comprehension. *Q J Exp Psychol.* 2008;61(6):825–50.
154. Glenberg AM, Kaschak MP. Grounding language in action. *Psychon Bull Rev.* 2002;9(3):558–65.
155. Gallistel CR. The organization of action: a new synthesis. Hillsdale: Lawrence Erlbaum; 1980.
156. Poulet JF, Hedwig B. The cellular basis of a corollary discharge. *Science.* 2006;311(5760):518–22.
157. Blakemore SJ, Wolpert D, Frith C. Why can't you tickle yourself? *NeuroReport.* 2000;11(11):R11–6.
158. Hesse MD, Nishitani N, Fink GR, Jousmaki V, Hari R. Attenuation of somatosensory responses to self-produced tactile stimulation. *Cereb Cortex.* 2010;20(2):425–32.
159. Bays PM, Flanagan JR, Wolpert DM. Attenuation of self-generated tactile sensations is predictive, not postdictive. *PLoS Biol.* 2006;4(2):e28.
160. Bays PM, Wolpert DM, Flanagan JR. Perception of the consequences of self-action is temporally tuned and event driven. *Curr Biol.* 2005;15(12):1125–8.
161. Diedrichsen J, Hashambhoy Y, Rane T, Shadmehr R. Neural correlates of reach errors. *J Neurosci.* 2005;25(43):9919–31.
162. Isope P, Dieudonne S, Barbour B. Temporal organization of activity in the cerebellar cortex: a manifesto for synchrony. *Ann NY Acad Sci.* 2002;978:164–74.
163. Jacobson GA, Rokni D, Yarom Y. A model of the olivocerebellar system as a temporal pattern generator. *Trends Neurosci.* 2008;31(12):617–25.
164. Llinas R, Leznik E, Makarenko VI. On the amazing olivocerebellar system. *Ann NY Acad Sci.* 2002;978:258–72.
165. Peach B. Arnold-Chiari malformation: anatomic features of 20 cases. *Arch Neurol.* 1965;12:613–21.
166. Bastian AJ. Understanding sensorimotor adaptation and learning for rehabilitation. *Curr Opin Neurol.* 2008;21(6):628–33.

167. Imamizu H, Miyauchi S, Tamada T, Sasaki Y, Takino R, Putz B, et al. Human cerebellar activity reflecting an acquired internal model of a new tool. *Nature*. 2000;403(6766):192–5.
168. Clower DM, West RA, Lynch JC, Strick PL. The inferior parietal lobule is the target of output from the superior colliculus, hippocampus, and cerebellum. *J Neurosci*. 2001;21(16):6283–91.
169. Dennis M, Jewell D, Hetherington R, Burton C, Brandt ME, Blaser SE, et al. Verb generation in children with spina bifida. *J Int Neuropsychol Soc*. 2008;14(2):181–91.
170. Diedrichsen J, Criscimagna-Hemminger SE, Shadmehr R. Dissociating timing and coordination as functions of the cerebellum. *J Neurosci*. 2007;27(23):6291–301.
171. Sakai K, Hikosaka O, Nakamura K. Emergence of rhythm during motor learning. *Trends Cogn Sci*. 2004;8(12):547–53.
172. D'Angelo E, De Zeeuw CI. Timing and plasticity in the cerebellum: focus on the granular layer. *Trends Neurosci*. 2009;32(1):30–40.
173. Halligan PW, Fink GR, Marshall JC, Vallar G. Spatial cognition: evidence from visual neglect. *Trends Cogn Sci*. 2003;7(3):125–33.
174. Brozzoli C, Cardinali L, Pavani F, Farne A. Action-specific remapping of peripersonal space. *Neuropsychologia*. 2010;48(3):796–802.
175. Dennis M, Edelman K, Frederick J, Copeland K, Francis D, Blaser SE, et al. Peripersonal spatial attention in children with spina bifida: associations between horizontal and vertical line bisection and congenital malformations of the corpus callosum, midbrain, and posterior cortex. *Neuropsychologia*. 2005;43(14):2000–10.
176. Poretti A, Prayer D, Boltshauser E. Morphological spectrum of prenatal cerebellar disruptions. *Eur J Paediatr Neurol*. 2009;13(5):397–407.
177. Baillieux H, De Smet HJ, Dobbeleir A, Paquier PF, De Deyn PP, Mariën P. Cognitive and affective disturbances following focal cerebellar damage in adults: a neuropsychological and SPECT study. *Cortex*. 2010;46(7):869–79.
178. Dennis M, Edelman K, Copeland K, Frederick JA, Francis DJ, Hetherington R, et al. Space-based inhibition of return in children with spina bifida. *Neuropsychology*. 2005;19(4):456–65.
179. Huber-Okraieci J, Blaser SE, Dennis M. Idiom comprehension deficits in relation to corpus callosum agenesis and hypoplasia in children with spina bifida meningocele. *Brain Lang*. 2005;93(3):349–68.
180. Fletcher JM, Copeland K, Frederick JA, Blaser SE, Kramer LA, Northrup H, et al. Spinal lesion level in spina bifida: a source of neural and cognitive heterogeneity. *J Neurosurg Pediatr*. 2005;102(3):268–79.
181. Hasan K, Eluvathingal T, Kramer L, Ewing-Cobbs L, Dennis M, Fletcher J. White matter microstructural abnormalities in children with spina bifida myelomeningocele and hydrocephalus: a diffusion tensor tractography study of the association pathways. *J Magn Reson Imaging*. 2008;27(4):700–9.
182. Stoodley CJ, Schmahmann JD. Evidence for topographic organization in the cerebellum of motor control versus cognitive and affective processing. *Cortex*. 2010;46(7):831–44.
183. Fuentes CT, Bastian AJ. 'Motor cognition'—what is it and is the cerebellum involved? *Cerebellum*. 2007;6(3):232–6.
184. Umiltà C, Priftis K, Zorzi M. The spatial representation of numbers: evidence from neglect and pseudoneglect. *Exp Brain Res*. 2009;192(3):561–9.
185. Rizzolatti G, Sinigaglia C. The functional role of the parieto-frontal mirror circuit: interpretations and misinterpretations. *Nat Rev Neurosci*. 2010;11(4):264–74.
186. Ackermann H, Wildgruber D, Daum I, Grodd W. Does the cerebellum contribute to cognitive aspects of speech production? A functional magnetic resonance imaging (fMRI) study in humans. *Neurosci Lett*. 1998;247(2–3):187–90.
187. James KH. Sensori-motor experience leads to changes in visual processing in the developing brain. *Dev Sci*. 2010;13(2):279–88.
188. Dennis M, Landry SH, Barnes M, Fletcher JM. A model of neurocognitive function in spina bifida over the life span. *J Int Neuropsychol Soc*. 2006;12(02):285–96.
189. Barnes MA, Huber J, Johnston AM, Dennis M. A model of comprehension in spina bifida meningocele: meaning activation, integration, and revision. *J Int Neuropsychol Soc*. 2007;13(5):854–64.