

Improvement of obstructive sleep apneas caused by hydrocephalus associated with Chiari malformation Type II following surgery

Case report

MARCO LUIGETTI, M.D.,¹ ANNA LOSURDO, M.D.,¹ SERENA DITTONI, M.D.,¹
ELISA TESTANI, M.D.,¹ SALVATORE COLICCHIO, M.D.,¹ VALENTINA GNONI, M.D.,¹
BENEDETTO FARINA, M.D., PH.D.,² EMANUELE SCARANO, M.D.,³ GIUSEPPE ZAMPINO, M.D.,⁴
PAOLO MARIOTTI, M.D.,¹ CLAUDIA RENDELLI, M.D.,⁴ CONCEZIO DI ROCCO, M.D.,¹
LUCA MASSIMI, M.D.,¹ AND GIACOMO DELLA MARCA, M.D., PH.D.¹

Departments of ¹Neurosciences and ⁴Paediatrics; ³Institute of Otorhinolaryngology, Catholic University of Sacred Heart; and ²Faculty of Psychology, European University, Rome, Italy

Chiari malformation (CM) is the downward herniation of the caudal part of the cerebellum and/or medulla oblongata into the spinal canal. It can alter several neurological functions, including respiratory control and upper airway motility, and can be the cause of sleep-disordered breathing (SDB). The authors describe a 6-year-old boy affected by CM Type II associated with myelomeningocele who showed symptoms indicative of severe airway obstruction during sleep. Polysomnography revealed severe obstructive sleep apnea syndrome (OSAS). Magnetic resonance imaging demonstrated herniation of the cerebellar tonsils and diffuse ventricular dilation with a large pseudocystic formation in the third ventricle. Surgical marsupialization of the cystic wall was performed, associated with ventriculocystostomy and endoscopic replacement of the ventricular catheter. Polysomnography repeated 2 months after surgery revealed a striking improvement in the sleep-related respiratory pattern. The pathogenesis of OSAS was probably referable to a combination of CM and elevated intracranial pressure. However, the striking improvement of symptoms after ventriculoatrial shunt placement suggested that hydrocephalus plays a major role in this condition. Assessment and effective treatment of SDB is crucial in the care of patients with CM.

(DOI: 10.3171/2010.7.PEDS10207)

KEY WORDS • Chiari malformation Type II • hydrocephalus • polysomnography • obstructive sleep apnea syndrome

CHIARI malformation is defined as a downward herniation of the caudal part of the cerebellum and/or medulla oblongata into the spinal canal. This malformation is classified into at least 2 distinct types according to the degree of herniation: Type I, which displays herniation of the cerebellar tonsils; and Type II, which exhibits herniation of the fourth ventricle and the medulla oblongata as well as the caudal part of the cerebellum.¹¹ Chiari malformation Type II is associated with more severe malformations, particularly with myelomeningocele.¹⁴ Syringomyelia and basilar invagination can also be associated with CM; they can alter the function of respiratory centers and cause SDB.^{1,2,4,10,18} Not only cen-

tral,^{3,10,18} but also obstructive,^{2,4} respiratory events due to sleep-related upper airway collapse have been reported in CM. Some reports seem to indicate that SDB and, in particular, central apneas^{3,18} may improve in patients with CM following surgical decompression of the posterior fossa.

We describe the clinical, neuroradiological, and polysomnographic findings in a 6-year-old boy affected by CM Type II with myelomeningocele and severe sleep-related airway obstruction, who showed a dramatic improvement after surgical treatment.

Case Report

History. This 6-year-old boy, affected by CM Type 2 associated with myelomeningocele and hydrocephalus, presented with symptoms of SDB. The parents had observed

Abbreviations used in this paper: CM = Chiari malformation; OSAS = obstructive sleep apnea syndrome; PSG = polysomnography; SDB = sleep-disordered breathing; SpO₂ = peripheral hemoglobin saturation.

Obstructive sleep apneas caused by hydrocephalus

loud, intermittent snoring and frequent respiratory pauses during sleep. At the age of 6 months he underwent, for referred swallowing difficulties, surgical plasty of the malformation with decompression of the posterior fossa and ventriculoatrial shunt placement. The symptoms slightly improved after surgery. The child never presented with seizures, and no antiepilepsy treatment was ever started.

Examination. Neurological examination showed moderate language developmental delay, divergent strabismus, moderate dysphagia (especially for liquids), paraplegia with severe bilateral sensory impairment in the lower limbs, bilateral clubfoot, and neurological bladder. Muscular strength and sensory examination in the upper limbs were normal. Extensive laboratory studies, including blood gas analysis, chest radiography, electrocardiography, and echocardiography, proved nondiagnostic. Otorhinolaryngoiatric evaluation showed adenoidal hyperplasia, but no anatomical obstruction of the upper airways was detected. In particular, the patient did not present with vocal chord palsy.

Neuroimaging. Magnetic resonance imaging (Fig. 1A and B) showed deep downward herniation of the cerebellar tonsil to the level of C-3 and thinned corpus callosum with agenesis of the splenium. The most relevant finding, however, was diffuse ventricular dilation with a large (59 mm in the longest axis) pseudocystic formation in the third ventricle. No spinal signal abnormalities were evident; in particular, no syringomyelic cavity and no basilar invagination were present. Schisis of the neural arches was evident from the L-3 level to the sacrum (images not shown).

Polysomnography. A PSG recording was performed at home using an ambulatory polygraph. On the recording night the child was allowed to follow his routine sleep-wake schedule. The recording montage included recordings of airflow, thoracic and abdominal respiratory effort, SpO₂, body position, snoring, and heart rate. Scoring of the polygraphic recordings was performed visually, according to the criteria proposed by Iber et al.⁷ Polysomnography showed severe OSAS characterized by intermittent, loud snoring associated with continuous obstructive apneas and hypopneas. The Apnea-Hypopnea Index was 41 events/hour, the index for central events was 4 events/hour, the Oxygen Desaturation Index was 41 events/hour, and the nadir of SpO₂ was 40%. Clusters of apneas and desaturations could be observed with a periodicity suggesting their recurrence during phases of rapid eye movement (REM) sleep (Fig. 2A).

Operation. Considering the radiological findings and the sleep-related respiratory pattern, a surgical treatment was planned. According to a previously described technique,¹⁶ marsupialization of the cystic wall was performed, as was ventriculocystostomy and endoscopic replacement of the ventricular catheter.

Postoperative Course. Immediately after surgery a striking improvement in the sleep-related respiratory pattern was observed. In particular, the parents reported a consistent reduction in snoring and respiratory pauses.

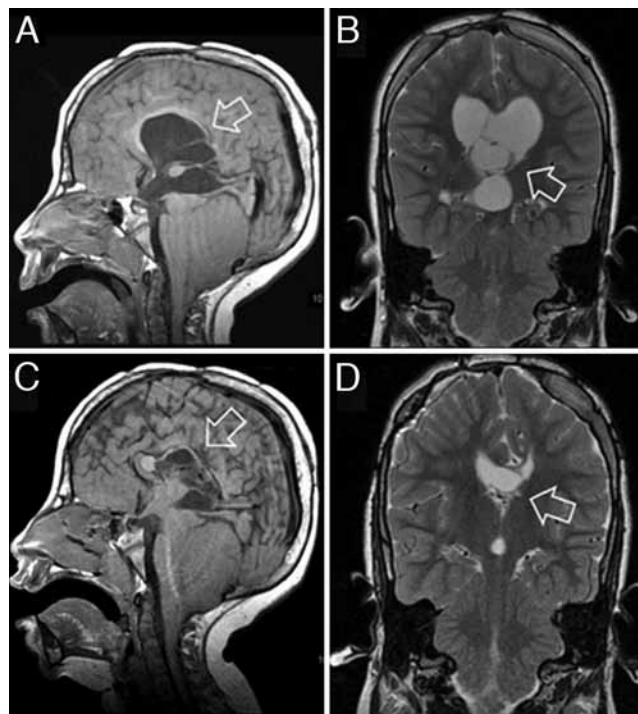

Fig. 1. Magnetic resonance images obtained before (A–B) and after (C–D) surgery. Sagittal T1-weighted (A) and coronal T2-weighted (B) images showing cystic dilation of the third ventricle. Herniation of the cerebellar tonsils below the foramen magnum is also visible on the sagittal scan (A). Follow-up sagittal T1-weighted (C) and coronal T2-weighted (D) MR images disclosing a marked reduction in the cystic dilation of the third ventricle. Herniation of the cerebellar tonsils below the foramen magnum is still evident on the sagittal scan (C). Arrow points to dilation of the third ventricle in each panel.

Computed tomography scans obtained immediately after surgery and an MR scan obtained 3 months after (Fig. 1C and D) showed a reduction in the hydrocephalus as well as the disappearance of cystic dilation of the third ventricle. Polysomnography repeated 2 months after surgery in the same setting revealed significant amelioration of the sleep-related respiratory pattern (Fig. 2B). Only sporadic obstructive events persisted, with mild SpO₂ falls. A marked reduction in the mean heart rate during sleep was observed. Detailed results of both PSG studies before and after surgery are listed in Table 1.

Discussion

The present case study concerns a child with CM Type II who, at the age of 6 years, showed symptoms and signs of a severe respiratory disorder during sleep. Notably, obstructive apneas were associated with hydrocephalus, and surgical treatment of the hydrocephalus was followed by a prompt and almost total resolution of the respiratory disorder.

Sleep-disordered breathing may be associated with CM, but relatively few data are available concerning the mechanisms, natural history, and treatment of SDB associated with CM.^{1,2} Most of the studies concern CM Type I or include only adult participants. Some reports indicate that CM Type I and II are associated with SDB

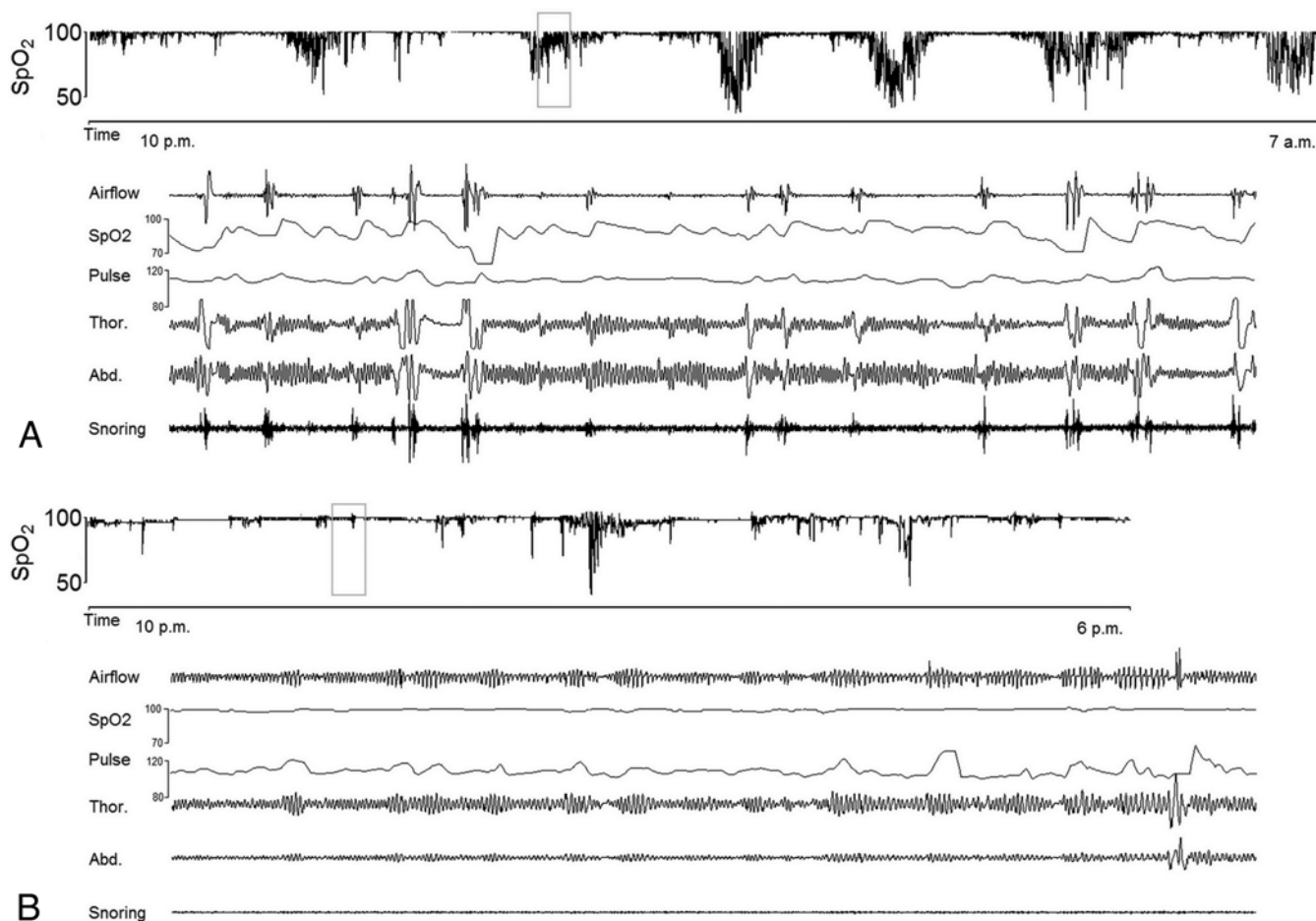


Fig. 2. Polygraphic recordings before **(A)** and after **(B)** surgery. The initial SpO₂ trace **(A)** shows clusters of desaturation events. A 15-minute portion of the polygraphic recording (*gray square*) is expanded; it shows repeated episodes of apneas (airflow channel) with the persistence of respiratory effort (abdominal and thoracic channels), associated with desaturation and intermittent snoring. The SpO₂ trace after surgery **(B)** discloses a marked reduction of desaturation events. A 15-minute portion of the polygraphic recording (*gray square*) is expanded; it shows normal respiratory findings.

of either central or obstructive origin.^{2-4,6,10,13,14,17,18} In the largest epidemiological study that has addressed the issue of SDB in patients with CM Type I and II,² OSAS was present in 57% of the adults and 35% of the children. Several pathogenic mechanisms can be involved in the genesis of central apneas in CM, including mechanical compression of the brainstem, depression of the respiratory center, damage of the reticular activating system,³ abnormal chemosensitivity due to damaged peripheral chemoreceptors,¹² and stretching of lower cranial nerves that carry afferent inputs from the carotid bodies to the medulla.¹² Associated malformations, such as syringomyelia and basilar invagination, may produce further neuronal dysfunction of the brainstem, cerebellum, cranial nerves, and upper spinal cord. Consequently, the respiratory center and some of its afferent and efferent components can be altered.¹

Conversely, the pathophysiological mechanisms underlying OSAS in CM remain unclear.² Obstructive events due to pharyngeal collapse may be related to an alteration in nervous control of upper airway patency during sleep. Moreover, CM may cause functional impairment of the ninth and tenth cranial nerves, which inner-

vate pharyngeal muscles, the critical segment involved in upper airway collapse during sleep.

Surgical decompression is the treatment of choice for neurological disturbances in patients with CM. Nevertheless, the effect of surgery is poorly predictable, and respiratory failure is a frequent complication. A reduction in central apneas following surgical decompression of the posterior fossa has been described,³ whereas few data are available concerning the effects of surgical treatment on obstructive events.

The patient herein described shows some peculiarities: SDB was very severe and characterized almost exclusively by obstructive events; OSAS was not associated with syringomyelia or other cervical cord abnormalities, nor to upper airway anatomical abnormalities; and the surgical treatment of hydrocephalus induced a rapid recovery of the sleep-related respiratory pattern, which was clearly demonstrated on follow-up PSG (Fig. 2B). In this case the pathogenesis of OSAS was probably referable to a combination of CM and elevated intracranial pressure. However, the striking improvement of symptoms after ventriculoatrial shunt placement suggests that hydrocephalus plays a major role in this condition. Sleep-disordered

Obstructive sleep apneas caused by hydrocephalus

TABLE 1: Results of the polysomnographic studies before and after surgery

Parameter	Before Op	After Op
recording time (min)	600	536
obstructive apneas (events/hr)	37	3
mixed apneas (events/hr)	4	1
central apneas (events/hr)	4	3
hypopneas (events/hr)	12	3
Apnea-Hypopnea Index (events/hr)	41	7
baseline SpO ₂ (%)	90	95
Desaturation Index (events/hr)	53	6
lowest SpO ₂ (%)	40	58
time w/ SpO ₂ <90% (%)	16	0
Snoring Index (events/hr)	9	3
mean heart rate (bpm)	111 ± 15	81 ± 28

breathing, and particularly OSAS, have been reported in patients with idiopathic adult hydrocephalus syndrome, but it was not ameliorated by lumbar CSF drainage or shunting, indicating nonreversible neurological damage induced by hydrocephalus.⁹ Abnormal respiratory findings have also been reported in patients with increased intracranial pressure due to brain tumors, with a decrease in the apneas after surgical removal of the lesion.¹⁵ It seems likely that hydrocephalus, and consequently increased intracranial pressure, can worsen the neuronal dysfunction in subtentorial structures caused by the deep herniation of cerebellar tonsils. Alternatively, it could be speculated that elevated intracranial pressure and ventricle dilation may impair some brain hemisphere functions essential for the maintenance of upper airway patency during sleep. Whatever the mechanism, the onset or worsening of a sleep-related respiratory disturbance could be the presenting symptom of increased intracranial pressure in patients with CM.

Sleep-disordered breathing in CM can be extremely serious, and the incidence of respiratory arrest and death during sleep seems to be increased in these patients.^{2,3,18} Moreover, obstructive apneas can contribute to further increases in intracranial pressure, inducing a vicious cycle that needs prompt treatment.^{5,8}

For these reasons, the assessment and effective treatment of SDB and upper airway obstruction during sleep are crucial in the care of patients with CM.

Disclosure

The authors report no conflict of interest concerning the materials or methods used in this study or the findings specified in this paper.

Author contributions to the study and manuscript preparation include the following. Conception and design: all authors. Acquisition of data: Losurdo, Dittoni, Testani, Colicchio, Gnoni, Farina, Zapino, Rendeli, Di Rocco, Massimi, Della Marca. Analysis and interpretation of data: Luigetti, Scarano, Massimi, Della Marca. Drafting the article: Luigetti, Farina, Scarano, Massimi. Critically revising the article: Luigetti, Gnoni, Farina, Della Marca. Reviewed final version of the manuscript and approved it for submission: all authors.

References

1. Botelho RV, Bittencourt LR, Rotta JM, Tufik S: A prospective controlled study of sleep respiratory events in patients with craniovertebral junction malformation. *J Neurosurg* **99**: 1004–1009, 2003
2. Dauvilliers Y, Stal V, Abril B, Coubes P, Bobin S, Touchon J, et al: Chiari malformation and sleep related breathing disorders. *J Neurol Neurosurg Psychiatry* **78**:1344–1348, 2007
3. Gagnadoux F, Meslier N, Svab I, Menei P, Racineux JL: Sleep-disordered breathing in patients with Chiari malformation: improvement after surgery. *Neurology* **66**:136–138, 2006
4. Gosalakal JA: Sleep-disordered breathing in Chiari malformation type 1. *Pediatr Neurol* **39**:207–208, 2008
5. Hayward R, Gonzalez S: How low can you go? Intracranial pressure, cerebral perfusion pressure, and respiratory obstruction in children with complex craniosynostosis. *J Neurosurg* **102** (1 Suppl):16–22, 2005
6. Hershberger ML, Chidekel A: Arnold-Chiari malformation type I and sleep-disordered breathing: an uncommon manifestation of an important pediatric problem. *J Pediatr Health Care* **17**:190–197, 2003
7. Iber C, Ancoli-Israel S, Chesson AL, Quan SF: **The AASM Manual for Scoring of Sleep and Associated Events: Rules, Terminology and Technical Specifications, ed 1.** Westchester, IL: American Academy of Sleep Medicine, 2007
8. Jennum P, Børgesen SE: Intracranial pressure and obstructive sleep apnea. *Chest* **95**:279–283, 1989
9. Kristensen B, Malm J, Rabben T: Effects of transient and persistent cerebrospinal fluid drainage on sleep disordered breathing in patients with idiopathic adult hydrocephalus syndrome. *J Neurol Neurosurg Psychiatry* **65**:497–501, 1998
10. Murray C, Seton C, Prelog K, Fitzgerald DA: Arnold Chiari type I malformation presenting with sleep disordered breathing in well children. *Arch Dis Child* **91**:342–343, 2006
11. Nishikawa M, Sakamoto H, Hakuba A, Nakanishi N, Inoue Y: Pathogenesis of Chiari malformation: a morphometric study of the posterior cranial fossa. *J Neurosurg* **86**:40–47, 1997
12. Nogués MA, Roncoroni AJ, Benarroch E: Breathing control in neurological diseases. *Clin Auton Res* **12**:440–449, 2002
13. Park TS, Hoffman HJ, Hendrick EB, Humphreys RP: Experience with surgical decompression of the Arnold-Chiari malformation in young infants with myelomeningocele. *Neurosurgery* **13**:147–152, 1983
14. Paul KS, Lye RH, Strang FA, Dutton J: Arnold-Chiari malformation. Review of 71 cases. *J Neurosurg* **58**:183–187, 1983
15. Pollak L, Shpirer I, Rabey JM, Klein C, Schiffer J: Polysomnography in patients with intracranial tumors before and after operation. *Acta Neurol Scand* **109**:56–60, 2004
16. Tamburrini G, D'Angelo L, Paternoster G, Massimi L, Caldarelli M, Di Rocco C: Endoscopic management of intra and paraventricular CSF cysts. *Childs Nerv Syst* **23**:645–651, 2007
17. Tsara V, Serasli E, Kimiskidis V, Papagianopoulos S, Katsaridis V, Fylaktakis M, et al: Acute respiratory failure and sleep-disordered breathing in Arnold-Chiari malformation. *Clin Neurol Neurosurg* **107**:521–524, 2005
18. Zolty P, Sanders MH, Pollack IF: Chiari malformation and sleep-disordered breathing: a review of diagnostic and management issues. *Sleep* **23**:637–643, 2000

Manuscript submitted May 6, 2010.

Accepted July 21, 2010.

Address correspondence to: Marco Luigetti, M.D., Institute of Neurology, Department of Neurosciences, Catholic University of Sacred Heart, Rome-Italy, Largo F. Vito 1, 00168 Roma, Italy. email: mluigetti@gmail.com.