



Contents lists available at ScienceDirect

Seminars in Fetal & Neonatal Medicine

journal homepage: www.elsevier.com/locate/siny

Fetal myelomeningocele: Natural history, pathophysiology, and in-utero intervention

N. Scott Adzick*

Center for Fetal Diagnosis and Treatment, Children's Hospital of Philadelphia and the University of Pennsylvania School of Medicine, 34th Street & Civic Center Blvd, Philadelphia, PA 19104, USA

S U M M A R Y

Keywords:

Fetal surgery
Hydrocephalus
Myelomeningocele
Prenatal diagnosis
Spina bifida

Myelomeningocele (MMC) is a common birth defect that is associated with significant lifelong morbidity. Little progress has been made in the postnatal surgical management of the child with spina bifida. Postnatal surgery is aimed at covering the exposed spinal cord, preventing infection, and treating hydrocephalus with a ventricular shunt. In-utero repair of open spina bifida is now performed in selected patients and presents an additional therapeutic alternative for expectant mothers carrying a fetus with MMC. It is estimated that about 400 fetal operations have now been performed for MMC worldwide. Despite this large experience, the technique remains of unproven benefit. Preliminary results suggest that fetal surgery results in reversal of hindbrain herniation (the Chiari II malformation), a decrease in shunt-dependent hydrocephalus, and possibly improvement in leg function, but these findings might be explained by selection bias and changing management indications. A randomized prospective trial (the MOMS trial) is currently being conducted by three centers in the USA, and is estimated to be completed in 2010. Further research is needed to better understand the pathophysiology of MMC, the ideal timing and technique of repair, and the long-term impact of in-utero intervention.

© 2009 Elsevier Ltd. All rights reserved.

1. Introduction

Open spina bifida or myelomeningocele (MMC) is a devastating congenital defect of the central nervous system for which there is no cure. It is characterized by protrusion of the meninges and spinal cord through open vertebral arches leading to lifelong paralysis. In addition, MMC patients are often limited by various degrees of mental retardation, bowel and bladder dysfunction, and orthopedic disabilities. While the etiology of MMC remains poorly understood, primary failure of either neural tube or mesenchymal closure at the caudal neuropore in the embryonic period results in exposure of the developing spinal cord to the uterine environment.^{1,2} Without protective tissue coverage, secondary destruction of the exposed neural tissue by trauma or amniotic fluid may occur throughout gestation. Until a decade ago, treatment of MMC consisted of surgical closure of the spinal canal at birth and lifelong supportive care. Recent reports of mid-gestational human repair indicate that in-utero repair may improve neurologic function and reduce morbidity from hydrocephalus and the Arnold–Chiari II malformation by reversal of the hindbrain herniation component. This

review will focus on the rationale for in-utero repair in the context of pathologic observations, animal models of MMC, and outcomes from the initial experience with human fetal MMC repair.

Advances in prenatal diagnosis now permit diagnosis of spina bifida as early as the first trimester, and extensive research into the etiology of neural tube defects has elucidated both genetic and micronutrient causes.³ While substantial progress could be made in preventing this disorder through folic acid supplementation, many women of childbearing age are unaware of the relationship between folic acid and neural tube defects.^{4,5} Consequently, spina bifida still affects nearly 1 in 2000 live births.^{6–8} Not included in this number are the estimated 23% of MMC pregnancies in which the fetus is aborted.^{9,10} Mothers who choose to continue the pregnancy must prepare for a child with significant care needs and high medical expenses. Despite aggressive intervention, nearly 14% of all spina bifida neonates do not survive past 5 years of age, with the mortality rising to 35% in those with symptoms of brainstem dysfunction secondary to the Arnold–Chiari malformation.¹¹ Whereas 70% of patients have an IQ >80, only half are able to live independently as adults, even with adapted accommodations.¹² The emotional and financial impact on the family and community are enormous. No recent data are available, but in 1994 the cost of care exceeded US \$500 million per year (in 1992 dollars) in the USA alone.¹³

* Tel.: +1 215 590 2727; fax: +1 215 590 4875.

E-mail address: adzick@email.chop.edu

In addition to motor and sensory deficits due to the spinal cord lesion, significant complications in MMC come from hydrocephalus, the Arnold–Chiari II malformation, and spinal cord tethering at the site of surgical repair. Hydrocephalus, defined as any enlargement of the cerebral ventricles, occurs in more than 85% of patients with MMC.¹⁴ At least 80% of spina bifida patients require placement of shunts to prevent the neurologic and intellectual compromise that accompanies significant ventriculomegaly, and 46% have complications of shunts within the first year of placement.^{15,16} Almost all patients with MMC also have the Arnold–Chiari II malformation, characterized by descent of the cerebellar vermis through the foramen magnum, elongation and kinking of the medulla, caudal displacement of the cervical spinal cord and medulla, and obliteration of the cisterna magna.¹⁷ Descent of the hindbrain through the foramen magnum can lead to brain stem compression, the leading cause of mortality in children with MMC.¹⁵ Clinical presentation of this malformation depends on the age of the child, but typically it includes dysfunction of the cerebellum, medullary respiratory center, and cranial nerves IX and X as well as hydrocephalus. Surgical management for symptomatic hindbrain herniation is beneficial in only selected patients and consists of a ventricular shunt, though some patients ultimately require laminectomy and decompression of the cranio-cervical junction.¹⁸ Tethering is fixation of the spinal cord secondary to adhesions between the previously exposed neural elements and the surrounding tissues, leading to tension on the neural axis. The diagnosis is confirmed radiographically, usually after a patient develops progressive worsening of neurologic function. While surgical release can limit further damage in some patients, the functional decline may be irreversible in others.^{19,20} Therapeutic interventions aimed at preventing these complications could significantly impact the quality of life of children with MMC. In-utero intervention may hold the key for reversing the hindbrain herniation, limiting the need for ventriculoperitoneal shunting due to hydrocephalus, and preventing late loss of function due to tethering.

2. Rationale for in-utero intervention

The neural damage in MMC may be primarily the result of defective spinal cord development, a secondary event resulting from damage to the exposed spinal cord by the intrauterine milieu, or both – the ‘two-hit hypothesis’. The two-hit hypothesis states that primary congenital abnormalities in anatomic development allow a relatively normal spinal cord to become secondarily damaged by amniotic fluid exposure, direct trauma, hydrodynamic pressure, or a combination of these factors. It is this secondary damage which may be ameliorated by early fetal surgical repair.

There are many observations that support this premise. Hutchins and colleagues performed a pathologic examination of the spinal cords of eight stillborn human fetuses with MMC and carefully described the relationships of the spinal cord, meninges, and dermal–epidermal junction.²¹ There were varying degrees of neural tissue loss at the site of the defect, but normal-appearing dorsal and ventral horns were present at the proximal aspect of the lesion. This group was among the first to suggest the two-hit pathophysiology since they attributed these alterations to injuries occurring subsequent to primary neural tube formation. A study of ten additional fetuses produced similar findings.²²

Additional support for the two-hit hypothesis of spinal cord damage comes from sonographic observation of fetuses with MMC. Multiple studies have assessed the quality, frequency, and presence of fetal leg movements during fetal development, only to report inconsistency between prenatal and postnatal function. Korenromp used sonography to document normal flexion and extension at the hips and knees as early as 16–17 weeks in MMC fetuses.²³ Sival studied the leg movements of 13 fetuses with MMC and compared

the results to postnatal function.²⁴ Only one of the 13 had abnormal leg movements prenatally, but 11 had abnormal postnatal leg movements. The leg movements seen prenatally could be secondary to spinal arc reflexes rather than of cerebral origin, thus permitting motion without electrical impulses through damaged segments of spinal cord. Alternately, the leg motions could come from the cerebrum through an intact spinal cord that is damaged secondarily throughout gestation, in labor and/or at delivery. Unfortunately, this study did not correlate the neurologic findings with the route of delivery. As is illustrated by these studies, accurate neurologic assessment in utero of the fetus with MMC remains a challenge.

Further support for the theory of acute neurologic damage comes from studies demonstrating improved neurologic outcomes following cesarean section prior to the onset of labor. Luthy reported 160 infants with MMC and compared outcomes based on vaginal delivery, cesarean section prior to the onset of labor, and cesarean section after the onset of labor. Delivery by cesarean section before the onset of labor resulted in better motor function at two years of age than with vaginal delivery or delivery by cesarean section after a period of labor.²⁵ In a subsequent report by this same group, the cesarean section groups were further stratified into patients with or without preoperative rupture of the amniotic membranes.²⁶ They noted improved outcomes, as measured by the difference in the mean between anatomic level and motor level, in those who had cesarean section after onset of labor but before rupture of membranes, as compared to those who underwent cesarean section after onset of labor with rupture of membranes. They concluded that labor prior to membrane rupture causes minimal injury to the protruding nervous tissue, and that loss of amniotic fluid with labor after membrane rupture may lead to traumatic injury.

Although other studies have indicated that cesarean section for MMC may not impact neurologic outcome, no group has compared vaginal delivery with elective cesarean section of vertex fetuses prior to onset of labor or rupture of membranes in a randomized, controlled fashion.^{27,28} Until such a study is performed, it is common obstetrical practice that fetuses with MMC are delivered by cesarean section prior to the onset of labor or rupture of membranes to minimize potential trauma to the spinal cord.

Insight into the protection provided by spinal cord coverage also comes from analysis of some of the less severe variants of spinal dysraphism which are interesting ‘experiments of nature’. In cervical dysraphism, a cystic sac containing neuroglial tissue bulges through open posterior vertebral elements, but remains covered by a thick layer of skin. The neurological examination in these patients is typically normal or near normal.²⁹ Lipomyelomeningocele involves a spinal dysraphism in which a lipoma covers the neural elements, generally preventing herniation of the cord through the defect. Compared to MMC patients, patients with lipomeningocele typically have milder neurologic deficits including retained bowel and bladder continence, despite significant dysplasia of the caudal spinal cord.³⁰ In hemimyelocele, half of the dysraphic spinal cord is devoid of dura and openly exposed to the uterine environment whereas the remaining half is covered with a dural membrane. In a study of 16 patients with this disorder, Duckworth reported that the dural encapsulated portion of the cord remained in complete continuity and corresponded to a lower extremity with normal or only mildly disturbed function.³¹ By contrast, the opposing limb varied in innervation and function.

3. Animal models

Multiple animal models of MMC have been developed to test the hypothesis that in-utero intervention can prevent further spinal

cord damage and the consequent neurologic deficits. The first was a primate (*Macaca mulatta*) model in which a fetal L3–5 laminectomy was performed late in gestation.³² The unrepaired fetuses showed cystic MMC-like lesions at birth and had neurologic deficits. A similar group of monkeys underwent immediate repair of the laminectomy in utero using allogeneic bone paste to reconstruct the resected dorsal arches. These fetuses repaired in utero were neurologically normal at birth. Unfortunately, the experiment did not include an initial procedure for creation of the defect with a period of exposure to the uterine environment prior to closure. Similar experiments by Heffez in fetal rats and pigs demonstrated increased loss of spinal cord tissue in a group not undergoing immediate repair.^{33,34} Stiefel studied the curly tail mouse model of exposed lumbosacral spina bifida and demonstrated progressive deterioration of neuroanatomic appearance and neurologic function with increasing gestational age.^{35,36} Danzer developed a retinoic acid-induced MMC in fetal rats and histopathology confirmed the entire spectrum of severity observed in human MMC as well as features of the Arnold–Chiari malformation.³⁷ While these studies support the principle of improved neurologic function with in-utero coverage of the spinal cord, a large animal model with prolonged periods of time in utero after surgical manipulation was needed before extrapolation of these findings to humans.

Beginning in 1993, a series of experiments was conducted by Martin Meuli, Scott Adzick, and colleagues, which demonstrated the similarities between a surgically created large animal model and human MMC and documented neurologic improvement following in-utero repair.^{38,39} A sheep model was created in fetal lambs at 75 days of gestation (term 145 days) by excision of skin, paraspinous musculature, vertebral arches of lumbar vertebrae 1 through 4, and the exposed dorsal dura mater. The pregnancy was then continued to near term, and cesarean section was performed at 140 days of gestation. The lambs developed lumbar cystic sacs with abnormal spinal cord tissue on the dorsal aspect. Histology revealed loss of neural tissue, disruption of neural bundles, and areas of cord necrosis in the exposed segments, strikingly similar to that seen in human MMC. The spinal cord and its coverings proximal to the lesion appeared normal. Clinically, the lambs demonstrated incontinence of urine and stool, flaccid paraplegia, as well as lack of sensation in the hindlimbs, which was confirmed by somatosensory evoked potentials.

Having demonstrated the feasibility of creating a spinal defect resembling human MMC, we then performed in-utero closure of the spine using this same model. Following creation of a spina bifida-type lesion at 75 days, the fetal lambs were operated on a second time at 100 days of gestation.^{39,40} A reversed latissimus dorsi flap was used to cover the exposed spinal cord placode, and the animals were delivered by Cesarean section just prior to term. Compared to the unrepaired group, the repaired group demonstrated near normal motor function, apparent continence of stool and urine, and intact sensation by clinical evaluation and somatosensory evoked potentials. Compared to normal postnatal sheep, the animals had some neurologic delay and hindlimb weakness, but they were able to stand, walk, and climb stairs. Histologically, the spinal cord, nerve roots, and spinal ganglia had well-preserved cytoarchitecture in all specimens, with only flattening and mild dilation of the central canal.

This was the first large animal experiment that demonstrated a spinal cord lesion could be created in utero and repaired at a later time point with preservation of neurologic function. Unlike the previous animal models, this sheep model more closely resembled that of human MMC in duration of exposure of the cord to the environment, clinical examination, and histology. These findings suggested that the uterine environment plays a significant role in secondary neural tissue destruction, perhaps even more than the

primary embryologic abnormality. Furthermore, it suggested that in-utero repair may permit preservation of neurologic function. Subsequent sheep studies have shown that this model, when combined with a lumbar myelotomy, leads to hindbrain herniation, and that in-utero closure results in reversal of hindbrain herniation.⁴¹

4. Clinical experience

Prior to 1997, we considered only fetuses with life-threatening anomalies and very poor predicted outcomes as candidates for fetal surgery. However, the severe morbidity and significant mortality of MMC combined with the promising results of animal research as well as the development of diagnostic ultrafast fetal magnetic resonance imaging (MRI) studies led to consideration of prenatal intervention for this disorder.

Expectant mothers considering in-utero therapy undergo extensive prenatal evaluation to include obstetrical evaluation, genetic screening, ultrasonography, and ultrafast MRI. Although most cases of MMC are isolated abnormalities, genetic screening permits identification of some of the genetic and chromosomal syndromes associated with spinal dysraphism. Ultrasonography assesses lower extremity function, identifies club foot anomalies, and estimates the spinal level of the defect by localizing vertebral arch defects. As a rule, fetuses with thoracolumbar defects have the worst functional outcomes, while those with progressively lower lesions tend to do better.^{42,43} Using ultrafast sequencing techniques for fetal MRI, we have been able to further define the presence or absence of the Arnold–Chiari malformation, hydrocephalus, and any other brain abnormalities.⁴⁴ By careful correlation of imaging results with known clinical outcomes, we have improved prenatal counseling of parents and planning of therapeutic interventions.

Because of the significant risks inherent in prenatal intervention, fetal surgery was initially offered only to those mothers in which the fetus had a large thoracolumbar defect, the Arnold–Chiari malformation, mild or moderate ventriculomegaly, normal leg movements, no apparent clubbing of the feet, normal karyotype, and absence of concomitant severe anomalies. Encouraging results with the first few patients led to surgical repair of smaller spinal defects, provided the other criteria are met. By limiting interventions to those with the Arnold–Chiari malformation, we target those most likely to suffer from hydrocephalus or life-threatening brain stem symptoms which require frequent postnatal surgical intervention.

Based on our experience with other fetal surgical interventions and observations in animal models, we speculated that the surgical procedure would be performed ideally between 19 and 25 weeks of gestation.³⁸ Repair at this age minimizes the length of time during which neuronal damage to the exposed cord may occur. Prior to this age, fetal tissues are quite gelatinous, making the procedure technically difficult. Additionally, we believed that early repair might limit progression of hydrocephalus, since increasing ventricular size over the course of gestation is characteristic of fetal MMC.⁴⁵

The preoperative counseling and intraoperative management of these patients is covered elsewhere in other chapters in this issue. In the operating room, the fetus is positioned with the MMC lesion visible through the uterine incision (Fig. 1). The cystic membrane of the MMC is carefully excised and the attachments of the meninges to the skin and soft tissues are detached. If possible, native dura alone is closed over the spinal cord as a first layer, followed by closure of paraspinous myofascial flaps, and then the skin surrounding the lesion is carefully mobilized and closed over to complete the repair. When the skin cannot be closed primarily, acellular human dermis graft can be used to complete the closure.

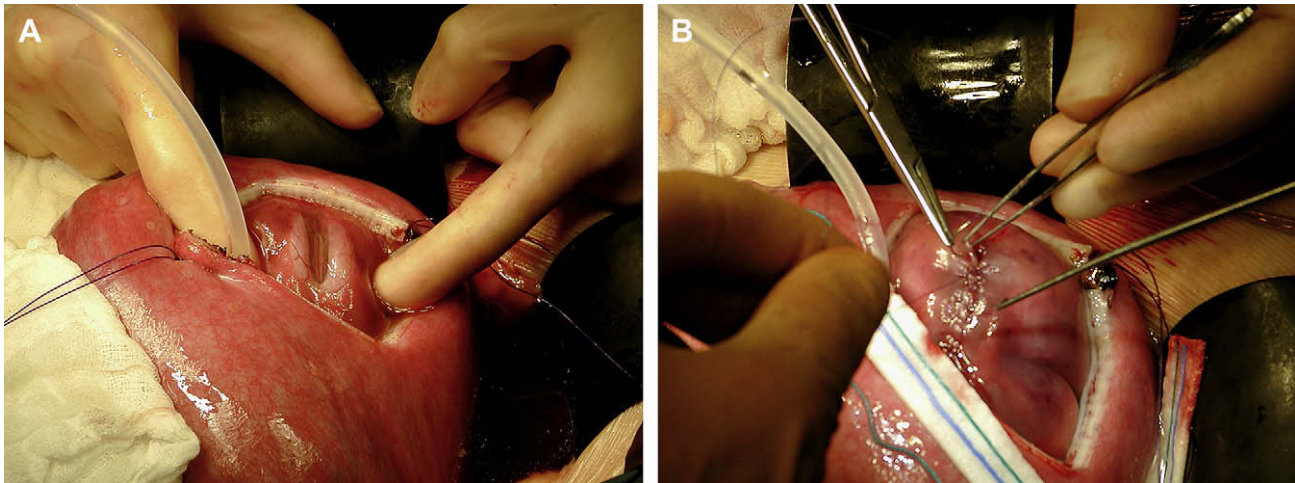


Fig. 1. (A) Exposure of 22 week gestation fetus through hysterotomy showing the myelomeningocele. (B) After dural closure and myofascial flap closure, the skin is closed.

Follow-up after hospital discharge included twice-weekly ultrasounds to assess for fetal wellbeing, ventriculomegaly, and evidence of fetal leg movement or clubbed feet. Ultrafast fetal MRI was performed every 3 weeks postoperatively in the first case series to further evaluate brain and spinal cord development. At 36 weeks, an amniocentesis was performed to confirm lung maturity and, if mature, the fetus was delivered by cesarean section. Physical examination, neurologic testing, and MRI were performed on the neonate and at regular intervals thereafter.

The first report of in-utero coverage of MMC came in 1997 from Tulipan and Bruner who described endoscopic placement of a maternal split-thickness skin graft over the fetal neural placode.⁴⁶ Of the two patients reported, one died shortly after surgery and the other showed no improvement in neurologic function. After abandoning the endoscopic technique, they subsequently reported four fetuses that underwent late gestation (28–30 weeks) open repair. Interestingly, all four patients demonstrated absence of hindbrain herniation at birth, but two required postnatal placement of a ventriculoperitoneal shunt and the neurologic outcome was not described.⁴⁷

We subsequently reported evidence of improved neurologic function following in-utero open fetal surgical repair earlier in gestation.⁴⁸ A 23 week gestation fetus with a T11–S1 dysraphic lesion and Arnold–Chiari malformation underwent open surgical repair. Seven weeks later at delivery the infant had a right club foot, but excellent flexion and extension at the knee and hip on that leg. The left leg had normal function except for absent plantar flexion of the foot. Whereas hindbrain herniation was documented preoperatively, postnatal MRI confirmed resolution of hindbrain herniation and absence of hydrocephalus. A ventriculoperitoneal shunt was not required. Unfortunately, this first patient developed severe tethering of the spinal cord at the repair site after 6 months of age, leading to loss of lower extremity function and requiring operative release. This late decline in function due to tethering underscores the importance of investigating better coverage materials and techniques for fetal MMC repair.

In 1999, we reported the findings of our first 10 patients who underwent fetal MMC closure at 22–25 weeks of gestation.⁴⁹ Nine remained in utero for an average duration of 10 weeks following surgery, and the remaining fetus delivered prematurely at 25 weeks of gestation and died from respiratory insufficiency. At birth, six of the nine patients had leg function at least two or more spinal segment levels better than expected based on prenatal MRI. All nine fetuses demonstrated ascent of the hindbrain and increased

cerebrospinal fluid (CSF) volumes around the posterior fossa by ultrafast fetal MRI assessment, consistent with hindbrain herniation reversal while still in utero. Four patients (44%) required postnatal placement of a ventriculoperitoneal shunt, one at the time of our report and three patients in subsequent follow-up. We hypothesize that fetal closure leads to more normal CSF pressure gradients with consequent ascent of the hindbrain, re-expansion of the cisterna magna, and improved CSF circulation.

At the same time, Bruner and colleagues reported decreased hindbrain herniation in 29 patients following MMC repair between 24 and 30 weeks of gestation.⁵⁰ Only 11 (38%) demonstrated any degree of postoperative cerebellar herniation, with moderate herniation present in two infants. In a comparison group of patients repaired postnatally, herniation was present in 95%. Likewise, 17 of the 29 patients (59%) required ventriculoperitoneal shunt placement and required it at a later postnatal age than the control group which had a 91% shunt placement rate (minimum follow-up of 6 months). Although improved leg function was not found in this group, exclusion of fetuses with preoperative evidence of decreased lower extremity function was not a component of their study. Additionally, the later gestational ages at time of repair may have contributed to the absence of improved neurologic function due to in-utero biochemical or traumatic damage. This fact was part of the rationale for repair before 26 weeks of gestation in the subsequent MOMS Trial.

We reported our experience with 58 patients treated with fetal surgery from 1998 to 2003 prior to the beginning of the MOMS Trial in 2003.⁵¹ There were four deaths due to preterm delivery, and the average age at delivery was 34 weeks, 4 days. Comprehensive follow-up examinations were performed at 1, 2, 3, and 5 years of age. There was resolution of hindbrain herniation in nearly all patients treated in utero, and the ascent of hindbrain structures could be demonstrated within 3 weeks of the fetal closure using serial MRI. The overall head size has been shown to be small in myelomeningocele patients, and to increase towards normal after fetal surgery due to normalization of extra-axial CSF spaces.⁵² Restoration of CSF volume in the posterior fossa after in-utero repair is indicative of reversal of hindbrain herniation. The functional significance is that the vast majority of children demonstrated no or minimal brain stem dysfunction symptoms at follow-up.⁵³ The ventriculoperitoneal shunt rate was 46%, which is much lower than the predicted overall shunt rate of 84% based upon 297 historical controls followed at the CHOP Spina Bifida Clinic between 1983 and 2000.⁵⁴ In assessing motor skills, fetal

surgery in this population resulted in better than predicted lower extremity function at birth, and ambulatory status at follow-up revealed that 66% were independent walkers.⁵⁵ However, toddlers and preschool children continue to demonstrate deficits in movement coordination and balance that are characteristic of children with spina bifida. Follow-up neuroanatomic imaging is important since we have seen postoperative intradural dermoid cysts develop at the fetal closure site.⁵⁶ Twenty-eight of the children have undergone neurodevelopmental evaluation at 5 years of age. The majority (83%) have overall cognitive functioning in the average to high range. There was a pattern of consistently higher scores in verbal areas compared to scores for visual-motor or non-verbal reasoning, suggesting the possibility of later learning difficulties.^{57,58}

The ramifications of these preliminary observations and outcomes are potentially significant. After fetal MMC repair, ascent of the hindbrain and improved CSF hydrodynamics may reduce hydrocephalus and avert the need for ventricular shunts with their associated morbidity. With a more normal anatomic location of the hindbrain, the symptomatic sequelae of the Arnold–Chiari malformation and need for subsequent surgery should be reduced. In the case of lower lumbar and sacral lesions where less impairment in lower extremity function may be predicted, normalizing hindbrain position and minimizing the need for postnatal ventriculoperitoneal shunt placement may be the primary indication for surgery. Persistence of improved lower extremity function, especially in patients with lesions at higher spinal levels, should permit greater independence and potentially improved quality of life. A reduction in the incidence of club feet and other orthopedic anomalies should limit the need for surgical intervention and enhance the possibility of future ambulation. The impact of prenatal intervention on bowel and bladder continence, sexual function, and mental capacity remains to be elicited as these infants advance in age and development.

5. A randomized, prospective clinical trial

A multicenter prospective randomized clinical trial of 200 patients (100 fetal repair, 100 postnatal repair) began in 2003: the Management of Myelomeningocele Study (MOMS). By early 2009, more than three-fourths of the proposed number of patients had been randomized. This trial is being conducted at CHOP, the University of California – San Francisco, and Vanderbilt University Medical Center, along with an independent Data and Study Coordinating Center at George Washington University Biostatistics Center. The trial is supported by the National Institutes of Health.

Potential patients are referred to the closest center based on geographic criteria. Patients willing to accept either procedure are randomized after consent either to prenatal surgery or to postnatal surgery at that center. All prenatal and postnatal patient care protocols have been standardized among the three centers. Patient inclusion criteria for the MOMS trial include: MMC at level T1–S1 with hindbrain herniation; maternal age ≥ 18 years; gestational age at randomization 19 weeks, 0 days to 25 weeks, 6 days; and normal karyotype. The patient exclusion criteria are: non-resident of the USA; multifetal pregnancy; insulin-dependent pregestational diabetes; fetal anomaly unrelated to MMC; fetal kyphosis ≥ 30 degrees; history of incompetent cervix; placenta previa; other serious maternal medical condition; short cervix < 20 mm by ultrasound; obesity; previous spontaneous singleton delivery before 37 weeks of gestation; fetal Rh isoimmunization; positive maternal human immunodeficiency virus or hepatitis B, or known hepatitis C positive; no support person to stay with the mother at the center; uterine anomaly; fails psychosocial evaluation; and inability to comply with travel and follow-up protocols.

The primary objective of the trial is to determine if intrauterine repair of fetal MMC at 19–25 weeks of gestation improves outcome, as measured by death or the need for shunting by one year of life, compared to postnatal MMC repair. Other objectives of the study are to determine whether fetal MMC repair improves the degree of Chiari II malformation and neurologic outcome as tested by neuroimaging, neuromotor function analysis, cognitive testing, and neurodevelopmental status at 12 and 30 months of age. Neonatal morbidity and the need for postnatal surgical interventions are recorded. Finally, the long-term psychological and reproductive consequences in mothers who undergo intrauterine repair of MMC are being compared to those in postnatal repair group. The investigators are blinded to all results and no preliminary data are available. The follow-up evaluation of the children is performed by an independent medical team. There is provision in the trial for periodic interim analysis by the Data Safety Monitoring Board, and thus far the study centers have been granted permission to continue. Patient accrual has been slower than expected. Prior to the beginning of the trial, all other centers in the USA voluntarily agreed not to offer fetal surgery for MMC outside of the trial, essentially closing a 'back door' to the intervention until the trial is completed.

Practice points

- Myelomeningocele (MMC) is a disease of high morbidity.
- Without protective tissue coverage, secondary destruction of the exposed neural tissue by trauma or amniotic fluid may occur throughout gestation.
- Prognosis is related to the anatomic level of the MMC, and severity of hydrocephalus and hindbrain herniation.
- Prenatal evaluation of a fetus with myelomeningocele who is being considered for fetal surgery should include high resolution ultrasound, magnetic resonance imaging, and amniocentesis.
- A thick-walled sac, absence of hindbrain herniation, and lack of elevation of maternal or amniotic fluid alpha-fetoprotein should raise suspicion of an occult spinal dysraphism such as lipomyelomeningocele or myelocystocele.

Research directions

- MOMS (Management of Myelomeningocele Study) is a multicenter prospective randomized trial in the USA comparing fetal repair with postnatal repair of MMC.
- Understand the prenatal pathophysiology.
- Elucidate the long-term impact of in-utero intervention.

Conflict of interest statement

None declared.

Funding source

The Management of Myelomeningocele Study (MOMS) is supported by a National Institutes of Health U10 grant.

References

1. Mitchell LE, Adzick NS, Melchionne J, Pasquariello PS, Sutton LN, Whitehead AS. Spina bifida. *Lancet* 2004;**364**:1885–95.
2. Hutchins GM, McGowan KD, Blakemore KJ. Spinal dysraphia: not a neural tube defect? *Am J Hum Genet* 1992;**51**:A319.

3. Botto LD, Moore CA, Khoury MJ, Erickson JD. Neural-tube defects. *N Engl J Med* 1999;**341**:1509–19.
4. Medical Research Council Vitamin Research Study Group. Prevention of neural tube defects: results of the Medical Research Council Vitamin Study. *Lancet* 1991;**338**:131–7.
5. Anonymous. Knowledge and use of folic acid by women of childbearing age – United States, 1995 and 1998. *Morb Mortal Wkly Rep* 1999;**48**:325–7.
6. Edmonds LD, James LM. Temporal trends in the prevalence of congenital malformations at birth based on the birth defects monitoring program, United States, 1979–1987. *MMWR CDC Surveill Summ* 1990;**39**:19–23.
7. Lary JM, Edmonds LD. Prevalence of spina bifida at birth – United States, 1983–1990: a comparison of two surveillance systems. *MMWR CDC Surveill Summ* 1996;**45**:15–26.
8. Shaw GM, Jensvold NG, Wasserman CR, Lammer EJ. Epidemiologic characteristics of phenotypically distinct neural tube defects among 0.7 million California births, 1983–1987. *Teratology* 1994;**49**:143–9.
9. Roberts HE, Moore CA, Cragan JD, Fernhoff PM, Khoury MJ. Impact of prenatal diagnosis on the birth prevalence of neural tube defects, Atlanta, 1990–1991. *Pediatrics* 1995;**96**:880–3.
10. Velie EM, Shaw GM. Impact of prenatal diagnosis and elective termination on prevalence and risk estimates of neural tube defects in California, 1989–1991. *Am J Epidemiol* 1996;**144**:473–9.
11. Oakeshott P, Hunt GM. Long-term outcome in open spina bifida. *Br J Gen Pract* 2003;**53**:632–6.
12. Hunt GM. Open spina bifida: outcome for a complete cohort treated unselectively and followed into adulthood. *Dev Med Child Neurol* 1990;**32**:108–88.
13. Waitzman NJ, Romano PS, Scheffler RM. Estimates of the economic costs of birth defects. *Inquiry* 1994;**31**:188–205.
14. Dias MS, McLone DG. Hydrocephalus in the child with dysraphism. *Neurosurg Clin N Am* 1993;**4**:715–26.
15. McLone DG. Results of treatment of children born with a myelomeningocele. *Clin Neurosurg* 1983;**30**:407–12.
16. Caldarelli M, DiRocco C, LaMarca F. Shunt complications in the first post-operative year in children with meningomyelocele. *Childs Nerv Syst* 1996;**12**:748–54.
17. Oaks W, Gaskill S. Symptomatic Chiari malformations in childhood. In: Park T, editor. *Spinal dysraphism*. Boston: Blackwell; 1992. p. 104–25.
18. McComb JG. Spinal and cranial neural tube defects. *Semin Pediatr Neurol* 1997;**4**:156–66.
19. Sarwark JF, Weber DT, Gabrieli AP, McLone DG, Dias L. Tethered cord syndrome in low motor level children with myelomeningocele. *Pediatr Neurosurg* 1996;**25**:295–301.
20. Fone PD, Vapnek JM, Litwiller SE, et al. Urodynamic findings in the tethered spinal cord syndrome: does surgical release improve bladder function? *J Urol* 1997;**157**:604–9.
21. Hutchins GM, Meuli M, Meuli-Simmen C, Jordan MA, Heffez DS, Blakemore KJ. Acquired spinal cord injury in human fetuses with myelomeningocele. *Pediatr Pathol Lab Med* 1996;**16**:701–12.
22. Meuli M, Meuli-Simmen C, Hutchins GM, Seller MJ, Harrison MR, Adzick NS. The spinal cord lesion in human fetuses with myelomeningocele: implications for fetal surgery. *J Pediatr Surg* 1997;**32**:448–52.
23. Korenromp MJ, Van Good JD, Bruinse HW, Kriek R. Early fetal movements in myelomeningocele. *Lancet* 1986;**1**:917–8.
24. Sival DA, Begeer JH, Staal-Schreinemachers AL, Vos-Niel JM, Beekhuis JR, Prechtel HF. Perinatal motor behaviour and neurological outcome in spina bifida aperta. *Early Hum Dev* 1997;**50**:27–37.
25. Luthy DA, Wardinsky T, Shurtleff DB, et al. Cesarean section before the onset of labor and subsequent motor function in infants with myelomeningocele diagnosed antenatally. *N Engl J Med* 1991;**324**:662–6.
26. Shurtleff DB, Luthy DA, Nyberg DA, Benedetti TJ, Mack LA. Meningomyelocele: management in utero and post natum. *Ciba Found Symp* 1994;**181**:270–86.
27. Merrill DC, Goodwin P, Burson JM, Sato Y, Williamson R, Weiner CP. The optimal route of delivery for fetal meningomyelocele. *Am J Obstet Gynecol* 1998;**179**:235–40.
28. Cochran D, Aronyk K, Sawatzky B, Wilson D, Steinbok P. The effects of labor and delivery on spinal cord function and ambulation in patients with meningomyelocele. *Childs Nerv Syst* 1991;**7**:312–5.
29. Pang D, Dias MS. Cervical myelomeningocele. *Neurosurgery* 1993;**33**:363–72.
30. Sutton LN. Lipomyelomeningocele. *Neurosurg Clin N Am* 1995;**6**:325–38.
31. Duckworth T, Sharrard WJ, Lister J, Seymour N. Hemimyocele. *Dev Med Child Neurol* 1968;**10**:69–75.
32. Michejda M. Intrauterine treatment of spina bifida. Primate model. *Z Kinderchir* 1984;**39**:259–61.
33. Heffez DS, Aryanpur J, Rotellini NA, Hutchins GM, Freeman JM. Intrauterine repair of experimental surgically created dysraphism. *Neurosurgery* 1993;**32**:1005–10.
34. Heffez DS, Aryanpur J, Hutchins GM, Freeman JM. The paralysis associated with myelomeningocele: clinical and experimental data implicating a preventable spinal cord injury. *Neurosurgery* 1990;**26**:987–92.
35. Steifel D, Copp AJ, Meuli M. Fetal spina bifida in a mouse model: loss of neural function in utero. *J Neurosurg* 2007;**106**:213–21.
36. Stiefel D, Meuli M. Scanning electron microscopy of fetal murine myelomeningocele reveals growth and development of the spinal cord in early gestation and neural tissue destruction around birth. *J Pediatr Surg* 2007;**42**:1561–5.
37. Danzer E, Schwarz U, Wehrli S, Radu A, Adzick NS, Flake AW. Retinoic acid induced myelomeningocele in fetal rats: characterization by histopathologic analysis and magnetic resonance imaging. *Exp Neurol* 2005;**194**:467–75.
38. Meuli M, Meuli-Simmen C, Yingling CD, et al. Creation of myelomeningocele in utero: a model of functional damage from spinal cord exposure in fetal sheep. *J Pediatr Surg* 1995;**30**:1028–32.
39. Meuli M, Meuli-Simmen C, Hutchins GM, et al. In utero surgery rescues neurologic function at birth in sheep with spina bifida. *Nat Med* 1995;**1**:342–7.
40. Meuli M, Meuli-Simmen C, Yingling CD, et al. In utero repair of experimental myelomeningocele saves neurologic function at birth. *J Pediatr Surg* 1996;**31**:397–402.
41. Bouchard S, Davey MG, Rintoul NE, Walsh DS, Rorke LB, Adzick NS. Correction of hindbrain herniation and anatomy of the vermis after in utero repair of myelomeningocele in sheep. *J Pediatr Surg* 2003;**38**:451–8.
42. Doran PA, Guthkelch AN. Studies in spina bifida: Part IV. The frequency and extent of paralysis. *J Neurol Neurosurg Psychiatr* 1963;**26**:545–51.
43. Cochran DD, Wilson RD, Steinbok P, et al. Prenatal spinal evaluation and functional outcome of patients born with myelomeningocele: information for improved prenatal counselling and outcome prediction. *Fetal Diagn Ther* 1996;**11**:159–68.
44. Quinn TM, Hubbard AM, Adzick NS. Prenatal magnetic resonance imaging enhances fetal diagnosis. *J Pediatr Surg* 1998;**33**:553–8.
45. Babcock CJ, Goldstein RB, Barth RA, Damato NM, Callen PW, Filly RA. Prevalence of ventriculomegaly in association with myelomeningocele: correlation with gestational age and severity of posterior fossa deformity. *Radiology* 1994;**190**:703–7.
46. Bruner JP, Tulipan NB, Richards WO. Endoscopic coverage of fetal open myelomeningocele in utero. *Am J Obstet Gynecol* 1997;**176**:256–7.
47. Tulipan N, Hernanz-Schulman M, Bruner JP. Reduced hindbrain herniation after intrauterine myelomeningocele repair: a report of four cases. *Pediatr Neurosurg* 1998;**29**:274–8.
48. Adzick NS, Sutton LN, Crombleholme TM, Flake AW. Successful fetal surgery for spina bifida. *Lancet* 1998;**352**:1675–6.
49. Sutton LN, Adzick NS, Bilaniuk LT, Johnson MP, Crombleholme TM, Flake AF. Improvement in hindbrain herniation by serial fetal MRI following fetal surgery for myelomeningocele. *J Am Med Assoc* 1999;**282**:1826–31.
50. Bruner JP, Tulipan N, Paschall RL, et al. Intrauterine repair of myelomeningocele, 'hindbrain restoration' and the incidence of shunt-dependent hydrocephalus. *J Am Med Assoc* 1999;**282**:1819–25.
51. Johnson MP, Adzick NS, Rintoul N, et al. Fetal myelomeningocele repair: short-term clinical outcomes. *Am J Obstet Gynecol* 2003;**189**:482–7.
52. Danzer E, Johnson MP, Bebbington M, et al. Fetal head biometry assessed by fetal magnetic resonance imaging following in utero myelomeningocele repair. *Fetal Diagn Ther* 2007;**22**:1–6.
53. Danzer E, Finkel RS, Rintoul NE, et al. Reversal of hindbrain herniation after fetal surgery for myelomeningocele subsequently reduces the incidence and severity of brain-stem dysfunction and cranial nerve compression. *Neuropediatrics*, in press.
54. Rintoul NE, Sutton LN, Hubbard AM, et al. A new look at myelomeningocele: functional level, vertebral level, shunting, and the implications for fetal intervention. *Pediatrics* 2002;**109**:409–13.
55. Danzer E, Gerdes M, Bebbington M, et al. Lower extremity neuromotor function and short-term ambulatory potential following in utero myelomeningocele surgery. *Fetal Diagn Ther* 2009;**25**:47–53.
56. Danzer E, Adzick NS, Rintoul NE, et al. Intraductal inclusion cysts following in utero closure of myelomeningocele: clinical implications and followup findings. *J Neurosurg Pediatr* 2008;**6**:406–13.
57. Johnson MP, Gerdes M, Rintoul NE, et al. Fetal surgery for myelomeningocele: neurodevelopmental outcomes at 2 years of age. *Am J Obstet Gynecol* 2006;**194**:1145–50.
58. Danzer E, Gerdes M, Zarnow DM, Bebbington M, Adzick NS, Johnson MP. Preschool neurodevelopmental outcome of children following fetal myelomeningocele closure. *Am J Obstet Gynecol* 2008;**199**:S15.